

Paediatric Intestinal Pseudo-obstruction: Evidence and Consensus-based Recommendations From an ESPGHAN-Led Expert Group

*†Nikhil Thapar, *Efstratios Saliakellis, ‡Marc A. Benninga, *Osvaldo Borrelli, §Joe Curry, ||Christophe Faure, ¶Roberto De Giorgio, #Girish Gupte, **Charles H. Knowles, ††Annamaria Staiano, ‡‡Yvan Vandenplas, and §§Carlo Di Lorenzo

ABSTRACT

Objectives: Chronic intestinal pseudo-obstructive (CIPO) conditions are considered the most severe disorders of gut motility. They continue to present significant challenges in clinical care despite considerable recent progress in our understanding of pathophysiology, resulting in unacceptable levels of morbidity and mortality. Major contributors to the disappointing lack of progress in paediatric CIPO include a dearth of clarity and uniformity across all aspects of clinical care from definition and diagnosis to management. In order to assist medical care providers in identifying, evaluating, and managing children with CIPO, experts in this condition within the European Society for Pediatric Gastroenterology, Hepatology, and Nutrition as well as selected external experts, were charged with the task of developing a uniform document of evidence- and consensus-based recommendations.

Methods: Ten clinically relevant questions addressing terminology, diagnostic, therapeutic, and prognostic topics were formulated. A systematic literature search was performed from inception to June 2017 using a number of established electronic databases as well as repositories. The approach of the Grading of Recommendations Assessment, Development and Evaluation (GRADE) was applied to evaluate outcome measures for the research questions. Levels of evidence and quality of evidence were assessed using the classification system of the Oxford Centre for Evidence-Based Medicine (diagnosis) and the GRADE system (treatment). Each of the recommendations were discussed, finalized, and voted upon using the nominal voting technique to obtain consensus.

Results: This evidence- and consensus-based position paper provides recommendations specifically for chronic intestinal pseudo-obstruction in infants and children. It proposes these be termed paediatric intestinal pseudo-obstructive (PIPO) disorders to distinguish them from adult onset CIPO. The manuscript provides guidance on the diagnosis, evaluation, and treatment of children with PIPO in an effort to standardise the quality of clinical care and improve short- and long-term outcomes. Key recommendations include the development of specific diagnostic criteria for PIPO, red flags to alert clinicians to the diagnosis and guidance on the use of available investigative modalities. The group advocates early collaboration with expert centres where structured diagnosis and management is guided by a multi-disciplinary team, and include targeted nutritional, medical, and surgical interventions as well as transition to adult services.

Conclusions: This document is intended to be used in daily practice from the time of first presentation and definitive diagnosis PIPO through to the complex management and treatment interventions such as intestinal transplantation. Significant challenges remain to be addressed through collaborative clinical and research interactions.

Key Words: intestinal transplantation, antroduodenal manometry, chronic intestinal pseudo-obstructive, gastrointestinal motility, intestinal pseudo-obstruction

(*JPGN* 2018;66: 991–1019)

Received August 16, 2017; accepted February 19, 2018.

From the *Neurogastroenterology and Motility Unit, Department of Paediatric Gastroenterology, Great Ormond Street Hospital NHS Foundation Trust, the †Stem Cells and Regenerative Medicine, UCL Great Ormond Street Institute of Child Health, London, United Kingdom, the ‡Emma Children's Hospital, Academic Medical Centre, Amsterdam, the §Neonatal and Paediatric Surgery Department, Great Ormond Street Hospital NHS Foundation Trust, London, United Kingdom, the ||Division of Pediatric Gastroenterology, Sainte-Justine Hospital, Université de Montréal, Montréal, Québec, Canada, the ¶Department of Medical and Surgical Sciences, Centro di Ricerca Biomedica Applicata (C.R.B.A.), St Orsola-Malpighi Hospital, University of Bologna, Bologna, Italy, the #Liver Unit, Birmingham Children's Hospital NHS Foundation Trust, Steelhouse Lane, Birmingham, the **Barts and the London School of Medicine and Dentistry, Queen Mary University, London, UK, the ††Department of Translational Medical Science, Section of Pediatrics, University of Naples "Federico II," Naples, Italy, the ‡‡Department of Paediatrics, UZ Brussel, Vrije Universiteit Brussel, Brussels, Belgium, and the §§Division of Pediatric Gastroenterology, Nationwide Children's Hospital, Columbus, OH.

Address correspondence and reprint requests to Nikhil Thapar, PhD, BM, MRCPCH, MRCP, BSc, Senior Lecturer and Honorary Consultant in Paediatric Gastroenterology, Great Ormond Street Hospital NHS Foundation Trust, Great Ormond Street, London, WC1N 3JH, United Kingdom (e-mail: n.thapar@ucl.ac.uk).

ESPGHAN is not responsible for the practices of physicians and provides guidelines and position papers as indicators of best practice only. Diagnosis and treatment is at the discretion of physicians.

Guideline development was financially supported by ESPGHAN. No support was received from industry.

N.T. is supported by Great Ormond Street Hospital Children's Charity.

N.T. has participated as clinical investigator, and/or advisory board member, and/or consultant, and/or speaker for Danone, Nutricia ELN and Mead Johnson. M.B. has participated as a consultant for Shire, Sucampo, AstraZeneca, Norgine, Coloplast, Danone, Frieslandcampina, Sensus, Novolac. R.D.G. has participated as a consultant for Shire, Sucampo, Coloplast, and Takeda. C.D.L. has participated as a consultant for Merck, Nestle, Sucampo, IMHealth, QOL. C.F. has participated as clinical investigator, and consultant for Sucampo. C.K. has received research support and continues to act as a paid consultant and speaker for Medtronic Inc. A.S. has participated as a clinical investigator, and/or advisory board member, and/or consultant, and/or speaker for Aboca, Angelini, Danone, D.M.G. Italy, Menarini, Miltè, Nestlé, Sucampo, and Valeas. Y.V. has participated as a clinical investigator, and/or advisory board member, and/or consultant, and/or speaker for Abbott Nutrition, Aspen, Biogaia, Biocodex, Danone, Hero, Kabrita, Nestle Nutrition Institute, Nutricia, Mead Johnson Nutrition, Merck, Olygose, Orafiti, Phacobel, Rontis, Sari Husada, United Pharmaceuticals, Wyeth and Yakult. The remaining authors report no conflicts of interest.

Copyright © 2018 by European Society for Pediatric Gastroenterology, Hepatology, and Nutrition and North American Society for Pediatric Gastroenterology, Hepatology, and Nutrition

DOI: 10.1097/MPG.0000000000001982

What Is Known

- Chronic intestinal pseudo-obstruction in childhood, are a heterogeneous and severe group of disorders
- There is poor understanding of aetiopathophysiology and limited data on epidemiology.
- There is lack of a globally accepted definition and diagnostic criteria for chronic intestinal pseudo-obstructive .
- Diagnostic and therapeutic approaches are variable and rates of morbidity and mortality remain high.

What Is New

- Chronic intestinal pseudo-obstructive in childhood is better termed paediatric intestinal pseudo-obstruction.
- Specific diagnostic criteria should be used for the diagnosis of paediatric intestinal pseudo-obstruction, including the utilisation of appropriate investigations.
- A more uniform and structured approach for the management of paediatric intestinal pseudo-obstruction is proposed.
- This initiative should aid the better understanding of aetiopathophysiology and epidemiology and overall outcomes.

INTRODUCTION

Chronic intestinal pseudo-obstruction (CIPO) is often regarded as the most severe end of a spectrum of gut motility disorders comprising a heterogeneous group of conditions affecting the structure and/or function of components of the intestinal neuromusculature (1). Although the advent of parenteral nutrition and intestinal transplantation in addition to considerable surgical expertise is now allowing cohorts of children with CIPO to survive into childhood, a number of significant challenges remain. Many of these have arguably hindered progress in this condition, which has meant that the prognosis of CIPO in children remains guarded at best, with up to 30% dying in childhood and the remaining facing a life plagued by significant morbidity and repeated hospitalizations (2–5). Considerable problems exist with regard to definition, terminology, criteria for diagnosis, and treatment. Not only is CIPO used as a blanket term for a very disparate group of aetiologies and pathologies, it also includes a range of severity from lethal conditions to those that may underlie more minor motility disorders. Furthermore, some of what has been applied to date in children with CIPO, including definition, has been extrapolated from studies in the adult equivalent of CIPO, even though we now recognise fundamental differences between the two conditions (6).

Given all of the above reasons it is, therefore not surprising that currently applied diagnostic criteria are vague and that the true incidence of CIPO in children remains unclear, although the condition is undoubtedly rare. As a result, there are often delays in definitive diagnosis and significant inconsistencies in the understanding, timing and nature of interventions. Treatments for many children with CIPO are unnecessary or unhelpful or escalated inappropriately and are themselves potentially likely to contribute to the high morbidity (2–4).

Our improved understanding and application of diagnostic tests and interventions in children with CIPO represent the rationale

for this initiative to bring together a group of experts across a number of related specialities from Europe and North America with the aim of developing an expert consensus on chronic intestinal pseudo-obstruction (CIPO) in children, henceforth referred to as paediatric intestinal pseudo-obstruction (PIPO). In addition to paediatric gastroenterologists, we have also included surgeons and experts in adult CIPO. The aim of this paper is to clarify a number of aspects in this condition in order to facilitate recognition, diagnosis, and timely and appropriate management. The ultimate goal is to establish better and more uniform clinical care based on evidence, where available, and expert consensus where it is not and to define an agenda for future initiatives and research as we start to unravel this most challenging clinical condition.

METHODS

In November 2014, a working group was formed consisting of European Society for Pediatric Gastroenterology, Hepatology, and Nutrition (ESPGHAN) and international experts involved in managing children with intestinal pseudo-obstruction and motility disorders. The working group's first meeting was used to formulate a series of clinical questions relevant to the clinical presentation, diagnosis and management of paediatric intestinal pseudo-obstruction (Table 1).

TABLE 1. Questions formulated by Paediatric Intestinal Pseudo-obstruction expert group

1. **Should Chronic Intestinal Pseudo-obstruction in infants and children be considered a distinct entity from adult CIPO?**
2. **What is the definition of Pediatric Intestinal Pseudo-obstruction?**
3. **What is the epidemiology of PIPO?**
4. **What are the signs, symptoms and comorbidities that suggest the diagnosis of PIPO?**
5. **In the diagnosis of PIPO what value do the following interventions / investigations carry?**
 - 5.1 Abdominal radiography
 - 5.2 Contrast and other Imaging studies
 - 5.3 Intestinal transit studies
 - 5.4 Manometry
 - 5.5 Surgery
 - 5.6 Histopathology: Role of histopathology in the diagnosis of PIPO
6. **Which of the following diagnostic tests should be performed in children with PIPO in order to diagnose an underlying disease (secondary CIPO)?**
 - 6.1 General laboratory tests
 - 6.2 Genetics
 - 6.3 Metabolic Screening
 - 6.4 Endoscopy
 - 6.5 Imaging
 - 6.6 Autonomic function testing
 - 6.7 Neurological Evaluation
7. **What is the role of the following management inputs and strategies in children with PIPO?**
 - 7.1 The multidisciplinary team (MDT)
 - 7.2 Nutrition
 - 7.3 Drugs / Pharmacotherapy
 - 7.4 Surgery
 - 7.5 Intestinal transplantation
8. **What are the outcomes and prognosis of PIPO and what factors contribute to these?**
9. **What is the optimal transition to adult life and clinical care for children with PIPO?**
10. **What clinical questions and research agenda should be addressed for PIPO in the future?**

After the questions were formulated, the working group members were subdivided into subgroups that dealt with the questions under each of the sections separately. Questions were answered using the results of systematic literature searches and based on expert opinion.

A systematic literature search was performed by one of the authors (ES) in January 2015 and updated again in December 2016 and members of the working group added further articles. MEDLINE, EMBASE, CINAHL, Cochrane Database of Systematic Reviews, Cochrane Central Register of Controlled Clinical Trials, and PsycInfo databases were searched.

Inclusion criteria were as follows:

1. Systematic reviews, prospective or retrospective controlled studies, prospective or retrospective cohort studies, clinical guidelines, clinical trials, cohort studies, case-control studies, diagnostic studies, surveys, letters, narrative reviews, and case series were included in the present review (we confined our search to publications in the English language only).
2. Study population consisting of children aged 0 to 18 years. The review of the evidence included both paediatric and adult data because paediatric data were often scarce.
3. The following text and key words were used to perform the literature search: “children,” “pediatrics,” “paediatrics,” “chronic,” “intestinal pseudoobstruction,” “intestinal pseudo-obstruction,” “CIPO,” “antroduodenal manometry,” “antro-duodenal manometry,” “gastrointestinal motility,” “gastrointestinal dysmotility,” “intestinal failure,” “intestinal transplantation,” “enteric neuropathy,” “enteric myopathy.” Additional strategies for identifying studies included using the keywords mentioned above to search in the reference lists of review articles and the included studies. Moreover, the search was supplemented with a hand search of conference proceedings to identify relevant abstracts.

The levels and quality of evidence for each of the included articles was then assessed (ES) using the classification system of the Oxford Centre for Evidence-Based Medicine (<http://www.cebm.net>) and the GRADE system. Grades of evidence for each statement are based on the grading of the literature. If no therapeutic studies were found, we decided to define the quality of evidence as “low.” Using the GRADE system, the quality of evidence was graded as follows (7–12):

1. **High (A):** Further research is unlikely to change our confidence in the estimate of effect.
2. **Moderate (B):** Further research is likely to have impact on our confidence in the estimate of effect and may change the estimate.
3. **Low (C):** Further research is very likely to have an impact on our confidence in the estimate of effect and likely to change the estimate.
4. **Very low (D):** Any estimate of effect is very uncertain.

Strength of recommendations was defined as follows:

Strong: when the desirable effects of an intervention clearly outweigh the undesirable effects, or they clearly do not. It should be noted that the expert group can make strong recommendations based on lesser evidence when high-quality evidence is impossible to obtain and the anticipated benefits strongly outweigh the harms. Strong recommendations are formulated as “the working group recommends (. . .).”

Weak: when the trade offs are less certain (either because of the low quality of evidence or because the evidence suggests that

desirable and undesirable effects are closely balanced). Weak recommendations are formulated as “the working group suggests (. . .).”

One of the authors (ES) systematically reviewed all the articles selected in the literature review and separated the articles according to the various subgroups. The summary tables of all the articles and their grading were sent to all the authors before they wrote their relevant sections.

Consensus Meeting and Voting

Three meetings were held in order to achieve consensus and formulate all the recommendations. The consensus was formally achieved through nominal group technique, a structured quantitative method. The group anonymously voted on each recommendation. A 9-point scale was used (1- strongly disagree to 9 -fully agree), and votes are reported by each recommendation. Consensus was reached if >75% of the working group members voted 6, 7, 8, or 9. Consensus was reached for all of the questions. A decision was made to present an algorithm (Fig. 1). The final draft of the guidelines was sent to all of the authors for approval in July 2017.

Question 1: Should CIPO in infants and children be considered a distinct entity from adult CIPO?

CIPO was first described in mid-20thcentury. In 1958, Dudley et al reported a series of 13 adult patients with symptoms suggestive of intestinal occlusion. These patients underwent exploratory laparotomies, which failed to identify a mechanical cause for their symptomatology (13). This led to the recognition of a group of CIPO disorders in both adults and children that were characterised by a chronic failure of the gastrointestinal tract to propel its contents, therefore mimicking mechanical obstruction, but in the absence of any lesion occluding its lumen (14). Traditionally, the diagnosis of CIPO has been reliant on clinical features, natural history and radiologic findings, with the hallmark of the latter being the presence of dilated gut with air fluid levels (14,15). This radiological finding has been considered essential for diagnosis of CIPO in adults and widely adopted for children as well (3,5,16,17). It is clear, however, that there are fundamental differences between adult and paediatric CIPO (Table 2): for example, in children there are more congenital and primary forms than in adults, there is more commonly an involvement of the bladder as part of a hollow visceral disease, and there is more often need for special means of alimentation, such as tube feeding or parenteral nutrition due to their higher energy requirements. Thus, we propose that CIPO occurring in children be referred to as PIPO, a term used in the remainder of this document.

Recommendations:

- The expert group recommends that CIPO occurring in infants and children be considered a separate entity from that in adults and be referred to as PIPO

LoE: Expert Opinion

GoR: Low

VOTE: 9,9,9,9,9,7,8,9,9,8,9,9 (100% agreement, recommendation accepted)

Question 2. What is the definition of PIPO?

The expert group proposed the following definition and diagnostic criteria for PIPO

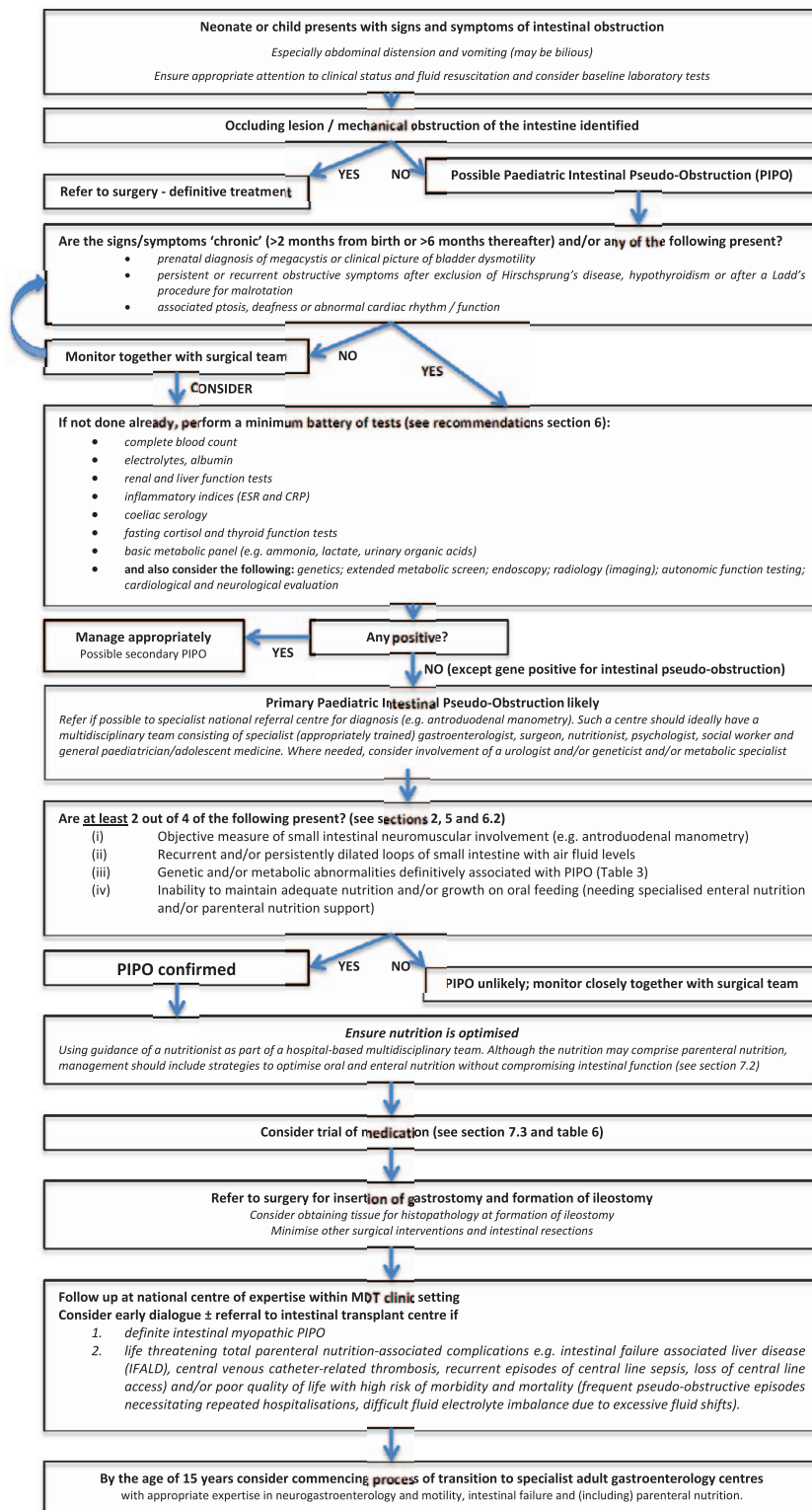


FIGURE 1. Suggested algorithm for the diagnosis and management of Paediatric Intestinal Pseudo-obstruction.

Paediatric intestinal pseudo-obstruction is a disorder characterised by the *chronic inability of the gastrointestinal tract to propel its contents mimicking mechanical obstruction,

in the absence of any lesion occluding the gut. *Chronic is defined as persistence for 2 months from birth or at least 6 months thereafter.

TABLE 2. Common and Distinctive Features of paediatric CIPO vs. adult CIPO (2,3,18–24)

	Children	Adults
Aetiology	Majority of cases appear to be congenital (up to 80%) and primary. Secondary forms rare (<10%)	Secondary forms (mostly to systemic disease) common and account for up to 50% of cases
Disease Subtype	Neuropathies more common (~70%) with myopathic forms seen in ~30%	Predominantly neuropathies (majority inflammatory) (~45%) with myopathies accounting for (~30%)
Symptom onset	In utero, from birth or early infancy (65–80% of patients by 12 months of age)	Median age of onset is 20 to 40 years
Clinical features	<ul style="list-style-type: none"> • Recurrent or continuous episodes of intestinal pseudo-obstruction with symptoms present from birth/early life • Pain infrequently seen (approximately 30%) • Urological involvement common (36–100%) • Intestinal malrotation in about 30% of cases • High risk of colonic and small bowel volvulus 	<ul style="list-style-type: none"> • Chronic abdominal pain and distension with superimposed acute episodes of pseudo-obstruction • Pain is a cardinal symptom present in at least 80% of patients • Urological involvement rare • Intestinal malrotation rarely seen • Low risk of colonic and small bowel volvulus
Natural history	Poor outcome predicted by myopathic forms of PIPO; urinary involvement; concurrent intestinal malrotation; and inability to tolerate enteral feeds Risk of mortality in approximately 20% of cases	Low mortality if ability to restore oral feeding and the presence of symptoms < 20 years of age; High mortality if systemic sclerosis or paraneoplasia and severe/diffuse oesophageal and intestinal dysmotility
Diagnostic approach	<ul style="list-style-type: none"> • Diagnosis relies on clinical picture and radiology together with specialised tests (eg, intestinal manometry, histopathology). • Dilated bowel loops with fluid levels commonly absent (~40%) in patients presenting in the neonatal period. • Histopathology yield high and used to inform management, for example, use of parenteral nutrition in intestinal myopathies and prokinetics in intestinal neuropathies • Apart from specific indications little yield from investigating for secondary PIPO • Need to differentiate from feeding problems and fabricated or induced illness. 	<ul style="list-style-type: none"> • Diagnosis made on clinical picture and radiology with variable use of intestinal manometry • On radiology defined by the presence of dilated loops of bowel with fluid levels • Histopathology has a positive yield in the majority of patients but guides treatment only in minority. • May help support a diagnosis of secondary CIPO with other clinical findings / investigations.
Nutritional therapy	Significant (~80%) require parenteral nutrition to maintain normal growth and development. Specialised feeds (eg, hydrolysed protein feeds) and feeding routes (eg, jejunal) used to promote enteral feed tolerance	Approximately 20–50% need home parenteral nutrition to prevent malnutrition
Pharmacological therapy	Virtually no evidence base from controlled trials. Use of medication mostly anecdotal, case reports or drawn from adult literature	Few controlled trials often small studies; few conclusions can be drawn
Surgical therapy	Venting ostomies very commonly used to decompress and reduce pseudo-obstructive events; Surgery as a 'bridge' to transplantation may be indicated in highly selected cases	Venting or defunctioning ostomies may help some patients. Little role for surgical resection

The diagnosis of PIPO requires at least 2 out of 4 of the following

- (i) Objective measure of small intestinal neuromuscular involvement (manometry, histopathology, transit*)
- (ii) Recurrent and/or persistently dilated loops of small intestine with air fluid levels
- (iii) Genetic and/or metabolic abnormalities definitively associated with PIPO (see Table 3 and section 6.2)
- (iv) Inability to maintain adequate nutrition and/or growth on oral feeding (needing specialised enteral nutrition and/or parenteral nutrition support).

* Practice point: essentially at present refers to use of small intestinal scintigraphic (nuclear medicine) studies and not contrast (barium or water-soluble) or "smart pill" studies, which have significant limitations. It should be noted, however, that at the present time there are no normative data for the former in children.

Recommendations:

- The expert group recommends that a uniform definition be applied to PIPO

LoE: Expert Opinion

GoR: Low

VOTE: 9,9,9,9,8,9,8,9,9,9,9 (100% agreement, recommendation accepted)

- The expert group recommends that uniform diagnostic criteria be used for the definitive diagnosis of PIPO

LoE: Expert Opinion

GoR: Low

VOTE: 9,9,8,9,9,8,8,9,9,9,9 (100% agreement, recommendation accepted)

TABLE 3. Classification of paediatric intestinal pseudo-obstruction

Primary PIPO

- Sporadic or familial forms of myopathy and/or neuropathy and/or mesenchymopathy (abnormal ICC development) that relate to disordered development, degeneration or inflammation. Inflammatory (including autoimmune) conditions include lymphocytic and eosinophilic ganglionitis and/or leiomyositis (25–49)
- Mitochondrial neuro-gastrointestinal-encephalomyopathy (MNGIE) and other mitochondrial diseases (50–53)
- neuropathy associated with multiple endocrine neoplasia type IIB (54–56)
- (Hirschsprung disease, for example, total intestinal aganglionosis)*

Secondary PIPO

- Conditions affecting GI smooth muscle:
 - Rheumatological conditions (dermatomyositis/polymyositis, scleroderma, systemic lupus erythematosus, Ehlers Danlos syndrome) (57–68)
 - Other (Duchenne muscular dystrophy, myotonic dystrophy, amyloidosis, ceroidosis or alternatively reported as brown bowel syndrome) (69–78)
 - Pathologies affecting the enteric nervous system (familial dysautonomia, primary dysfunction of the autonomic nervous system, neurofibromatosis, diabetic neuropathy, fetal alcohol syndrome, post-viral related inflammatory neuropathy, eg, Cytomegalovirus, Epstein–Barr virus, Varicella Zoster virus, JC virus) (79–94)
 - Endocrinological disorders (hypothyroidism, diabetes, hypoparathyroidism, pheochromocytoma) (95–99)
 - Metabolic conditions (uraemia, porphyria, electrolyte imbalances, eg, potassium, magnesium, calcium) (100–105)
 - Gastroschisis (106–108)
 - Neuropathy post neonatal necrotizing enterocolitis (109)
 - Other (coeliac disease, eosinophilic gastroenteritis, Crohn disease, radiation injury, Chagas disease, Kawasaki disease, angio-oedema, drugs, eg, opiates, anthraquinone laxatives, calcium channel blockers, antidepressants, anti-neoplastic agents, eg, vinca alkaloids, paraneoplastic CIPO, major trauma/surgery, chromosome abnormalities) (110–136)
- Idiopathic** (ie, where forms of primary or secondary PIPO classified as above do not, as yet, have a defined aetiopathogenesis)

*Needs to be excluded in all cases of PIPO.

Question 3: What is the epidemiology of PIPO?**EPIDEMIOLOGY**

PIPO is a rare disease with scant epidemiological data and poorly defined incidence and prevalence in both adult and paediatric populations. One of the few studies on its epidemiology suggested that approximately 100 infants are born in the United States every year with PIPO, suggesting an incidence of approximately 1 per 40,000 live births (23,137).

Adult studies reveal that the disease is more frequent in females (22,138,139). In a national survey conducted in Japan, 138 cases of CIPO were identified with an estimated prevalence of 1.0 and 0.8 cases, and incidence of 0.21 and 0.24 cases, per 100,000 males and females respectively (140). Also, in Japan a nationwide survey for PIPO was performed (141). This study revealed that among children younger than 15 years of age the prevalence of PIPO was 3.7 in one million children, of whom 56.5% had developed PIPO in the neonatal period. Overall, the available data suggests that PIPO is rare and is likely to have an incidence of less than 1 in 40,000, possibly even less than 1 in 100,000. It is not known, however, whether the epidemiology of PIPO is affected by geography, ethnicity or sex.

Contradicting evidence exists about the prognosis of these patients. Studies from France and the United States reported that in infants the disease appears to have a particularly severe course, with 60% to 80% requiring parenteral nutrition and 10%–25% dying before adulthood (2,3). However, the recent survey in Japan reported that only approximately 10% of the patients (6/62) were dependent on total parenteral nutrition (TPN). More importantly, only 4.8% (3/62) of the patients died from enteritis or sepsis, with no statistically significant difference in survival rate between the neonatal-onset and post-neonatal-onset groups ($P = 0.077$).

Uniform definitions and better recognition of this rare entity are a prerequisite to gain more insight in the prevalence of pseudo-obstruction in infants and children. Furthermore, the development of national registries is of paramount importance to delineate more precise epidemiologic characteristics of this orphan clinical entity. This will underpin the development of most appropriate clinical care by facilitating interactions designed to share clinical experience and expertise as well as drive much needed research forward.

Recommendations:

- The expert group recommends the development of robust national and international registries for PIPO in order to better delineate the epidemiological characteristics of PIPO.

LoE: Expert Opinion

GoR: Low

VOTE: 9,9,8,9,9,9,9,8,7,9,9 (100% agreement, recommendation accepted)

Question 4: What are the signs, symptoms and comorbidities that suggest the diagnosis of PIPO?**Signs and Symptoms**

The diagnosis of PIPO is difficult due to its variable clinical presentation and the lack of a single definitive diagnostic test. The diagnosis should be suspected in children presenting with symptoms of intestinal obstruction (defined as bile stained vomiting, failure to pass gas and stool and progressive abdominal distension) without an occluding lesion. The diagnosis of PIPO should be also considered when there is persistent vomiting after a Ladd procedure for malrotation (107) when intestinal obstruction is associated with bladder dysmotility or when, in a full term neonate, there is persistent or recurrent obstruction after exclusion of Hirschsprung disease and hypothyroidism.

The differential diagnosis should be carefully considered before proceeding down a diagnostic pathway for PIPO. Laboratory investigations, particularly the ones aiming at the identification of causes of secondary PIPO, should be guided by specific clinical signs and symptoms and are further discussed in section 6.

It should be noted that this section discusses the clinical presentation that should raise the suspicion for PIPO. As discussed above (diagnostic criteria; section 1) and below (diagnostic tools; section 5), its definitive diagnosis is likely to require clinical setting where specific motility expertise is available, including the use of more invasive specialized investigations. The diagnostic pathway needs to be carefully planned, structured and accurate, noting that the implications related to making a formal diagnosis of PIPO are profound both in terms of management and ultimate prognosis.

Prenatal Symptoms

Prenatal signs can be detected in about 20% of cases (3,4). Megacystis is the most frequently reported sign, whereas dilated bowel is quite rare. This has been noted in megacystis-microcolon-intestinal hypoperistalsis syndrome in which an antenatally enlarged bladder is seen by ultrasound in 88% of cases, hydronephrosis in 53%, increased volume of amniotic fluid in 34% and gastric distension in only 10% (142). Although some reports have described the detection of these signs by ultrasound as early as 16 weeks into the pregnancy, more often the abnormalities are noted very late in gestation (143). Antenatally diagnosed non-obstructive megacystis, with neonatal urological symptoms, may precede GI symptoms of pseudo-obstruction by several months.

Clinical Presentation After Birth

Age at Onset

Half to two thirds of patients present within the first month of life and 80% by one year of age. The remainder are detected sporadically throughout the first two decades of life (2–4,23). The clinical presentation is dependent upon the age at onset and the main symptoms are shown in Table 4.

Neonatal-onset Form

In the neonatal form, PIPO usually presents with abdominal distension with bilious vomiting. Abdominal radiographs may show dilated bowel loops with air-fluid levels suggestive of an intestinal obstruction. In megacystis-intestinal-hypoperistalsis syndrome, an obstructed urinary system leading to abdominal distension may be the presenting feature, with symptoms of intestinal obstruction appearing within days to 12 months later. In order to avoid unnecessary surgery, an exploratory laparotomy should be deferred in a neonate with antenatal diagnosis of megacystis. In these neonatal cases the air-fluid levels on radiographic studies may be missing. Some affected infants may present with abdominal distension and diarrhoea secondary to bacterial overgrowth.

PIPO may be mimicked by immaturity of intestinal motility in preterm infants, and thus, this diagnosis should be made with caution in this group given that the migrating motor complex (MMC) does not appear in its mature form until a gestational age of 34 to 35 weeks (144,145).

Infantile or Late-onset Form

The symptoms depend on the regions of the gastrointestinal tract involved. Patients present with subacute and/or recurrent episodes of gastric, intestinal and/or colonic obstruction leading to the

frequent need to put them “nil by mouth” accompanied by fluid replacement and gastric drainage (“drip and suck”). Symptoms may be acute or insidious and chronic. They may be persistent but are most often intermittent. Various triggers including intercurrent infections, fever, general anaesthesia and emotional stress may precipitate exacerbations. Diarrhoea due to bacterial overgrowth is frequent, and may alternate with constipation or episodes of partial obstruction. Stasis of intestinal contents is common in PIPO accompanied by reduced bowel sounds in contrast to mechanical obstruction, and chronic dilatation leads to decompensation and elongation of the bowel, further impairing motility. Dehydration (which can be severe) and malnutrition are often under-diagnosed especially given that weight can be an unreliable measure due to pooling of significant volumes of fluid (third spacing) within distended gut loops (146). Mechanical obstruction is normally absent in PIPO patients, but it can however be a complication of PIPO, especially after multiple surgical interventions. Volvulus of the splenic flexure and colonic volvulus have been reported in numerous PIPO cases due to torsion of fluid-filled bowel loops (147–149).

Abdominal pain, often in response to eating, may be severe enough to lead to feeding difficulties resulting in malnutrition. Notwithstanding the frequently detected oesophageal involvement by manometry, true dysphagia is rarely reported (150).

Recurrent episodes of functional partial bowel obstruction may be very difficult to differentiate from true mechanical obstruction in any child who has undergone a prior laparotomy and who may have developed adhesions.

The pancreatobiliary system may also be involved in PIPO. Dysmotility of the gall bladder and cholelithiasis (with or without related episodes of acute pancreatitis) may complicate the clinical picture and increase the morbidity and prognosis of this condition (151,152)

Urinary tract involvement occurs in 33% to 92% of cases, independent of the type of PIPO (3,153–155). Megacystis with a hypocontractile detrusor, increased bladder capacity and compliance is the most frequent pattern of urological abnormality (bladder adynamia). Uretero-hydronephrosis is seen in 56% to 68% of cases but vesico-ureteral reflux occurs in less than 10% (155). Urinary tract infections are frequent and may be asymptomatic. The renal prognosis is generally good, provided that careful evaluation and management of the adynamic bladder is performed in order to ensure adequate bladder emptying and to prevent urinary tract infection (155). Bladder biopsies show non-specific fibrotic changes in both neuropathic and myopathic forms of PIPO, and are thus not useful for subtype classification of PIPO.

Some patients present with significant colonic involvement usually manifest with progressively severe constipation (ie, <1 stool every 7–15 days), abdominal distension, bilious vomiting and failure to thrive. Following exclusion of Hirschsprung disease and

TABLE 4. Clinical symptoms in children with chronic intestinal pseudo-obstruction

Study	Abdominal distension	Vomiting	Constipation	Failure to thrive	Abdominal pain	Diarrhoea	Dysphagia
Faure et al n = 105	100	94	70	64	46	29	9
Vargas et al n = 87	73	50	51	23	NA	21	2
Granataet al n = 59	59	31	27	NA	NA	26	NA
Schuffler et al. {Schuffler, 1988 Krishnamurthy, 1993} n = 30	23	19	20	15	NA	16	NA
Heneyke et al n = 44	31	40	31	NA	NA	–	NA
Muto et al n = 62	55	33	9	NA	3	2	NA
Total n = 387	341 (88%)	267 (69%)	208 (54%)	102 (31%)	–	94 (24%)	11 (3%)

NA = not available.

of other causes of mechanical obstruction, PIPO should be considered and urinary symptoms should be carefully checked.

Comorbidities

Malrotation is frequent, especially in neonates (~30% of cases) (2–4), and has been reported in X-linked familial syndromes associating PIPO, malrotation, and pyloric non-hypertrophic stenosis (156–159).

The physical examination should involve a thorough neuromuscular assessment, including testing for pupillary reactions to light and accommodation and external ocular movements to help identify conditions associated with autonomic neuropathy or mitochondrial diseases. Testing for orthostatic stability should be sought as postural dizziness, visual disturbances, and sweating abnormalities suggest the presence of an underlying autonomic neuropathy (39). External ophthalmoplegia associated with deafness suggests a mitochondrial neuro-gastro-intestinal-encephalomyopathy (MNGIE) defect. In this condition, the onset of symptoms (gastrointestinal or ocular or both) generally occurs during adolescence, although very early-onset disease has been reported (5 months of age) (160). Peripheral neuropathy and diffuse muscle weakness are the predominant manifestations, although almost all patients have evidence of leukoencephalopathy on magnetic resonance imaging of the brain (52). Thymidine phosphorylase activity and plasma thymidine should be measured when suspecting such a diagnosis (161). Audiological assessment is important to rule-out deafness, detected in patients with a *SOX10* gene mutation (162,163). The dermatological examination should note signs of connective tissue disease (ie, scleroderma, dermatomyositis, lupus) including: Raynaud phenomenon, skin eruption, palmar erythema, telangiectasia, nodules, and scleroderma of the hands, feet, face and forearms. Digestive symptoms may precede the skin involvement in these disorders (164). Neural crest derived tumours and pheochromocytoma should be suspected and ruled out in children and infants with PIPO: appropriate CT imaging and ultrasound studies should be considered to exclude the presence of thoracic or abdominal tumours (165). Cardiac rhythm and function must be evaluated by ECG and echocardiography, since dysfunction of cardiac sinus node may be associated with PIPO (166) and abnormal cardiac contraction should lead the clinician to suspect muscular diseases, such as desmin myopathies (167).

Recommendations:

- The expert group recommends that a diagnosis of PIPO should be suspected in the following situations:
 1. In all children presenting with symptoms of intestinal obstruction without an occluding lesion.
 2. In neonates with:
 - Prenatal diagnosis of megacystis/enlarged bladder
 - Persistent or recurrent obstructive symptoms after exclusion of Hirschsprung disease and hypothyroidism.
 - Persistent vomiting after a Ladd procedure for malrotation
 - Symptoms of intestinal obstruction associated with bladder dysmotility
 3. In infants or children with:
 - Persistent or recurrent obstructive symptoms after exclusion of Hirschsprung disease

- Persistent vomiting/intestinal obstruction after correction of malrotation
- Symptoms of intestinal obstruction associated with
 - Ptosis
 - Deafness
 - Abnormal cardiac rhythm/function

LoE: 2

GoR: Moderate

VOTE: 8,9,9,9,7,9,8,9,7,7,9,9 (100% agreement, recommendation accepted)

Question 5: In the diagnosis of PIPO what value do the following investigations carry?

5.1 Abdominal Radiography?

In the retrospective cohort investigated by Faure and colleagues, 82% of patients had dilatation of at least one region of the gastrointestinal tract. Sixteen of the 18 patients with no dilatation were newborns or younger than 2 months (3). In the prospective cohort of Henyke et al among 44 paediatric patients diagnosed with PIPO, 10 were diagnosed with a distal bowel obstruction, while in 5 a paucity of intestinal gas was identified, and a malrotation successively diagnosed by contrast studies (4). In a recent study by Muto et al, a plain abdominal radiography was performed in all 62 patients enrolled at diagnosis. In all of them, dilation of the intestinal tract was detected; air fluid levels were identifiable in all of the patients diagnosed after the neonatal period, while only in 57% of patients during neonatal period (141).

Recommendations:

- The expert group recommends that abdominal radiography should be routinely used in all patients with a suspicion of PIPO as first screening to identify dilated small intestinal loops.

LoE: 2

GoR: Moderate

VOTE: 9,9,9,9,8,8,9,9,9,8,9,9 (100% agreement, recommendation accepted)

Practice points:

- Abdominal radiographs allow identification of the typical signs of intestinal occlusion, such as air-fluid levels and dilated bowel.
- Air fluid levels are better visualised in upright position; lateral decubitus view may be used in those children not able to have radiography in the upright position.
- A plain radiograph cannot be used as the only tool to diagnose PIPO, since it cannot differentiate functional from mechanical obstruction.
- Some form of contrast or axial imaging is therefore required to exclude mechanical obstruction.

5.2 Contrast and Other Imaging Studies?

Contrast studies play an important role in the initial assessment of children with suspected PIPO as they rule out the presence of fixed-lumen occluding lesions and gut malrotation. Small bowel follow-through (SBFT) studies have been traditionally considered the gold standard imaging tests, and in patients with PIPO they are usually performed using water-soluble contrast in order to avoid the possible formation of barium concretions in the colon. The SBFT may reveal a marked distension of the small bowel loop, mainly involving the stomach and the first part of the duodenum, very slow transit through an otherwise unremarkable intestine, and the presence of intestinal malrotation. In children with PIPO, the presence of a dilatation of at least one region of the gastrointestinal tract, as documented by a contrast study, ranges between 59% and 82% (3,4), whilst intestinal malrotation is found in up to 36% of patients (2–4). The SBFT is easy to perform, widely available and not expensive, but its use is hampered by inability of patients to ingest large amounts of unpalatable contrast, high radiation dose, and flocculation of the contrast meal. Newer methods of small-bowel investigation, predominantly cross-sectional techniques, such as entero-computed tomography (CT) and entero-magnetic resonance imaging (MRI), are now proposed as first-line modalities in patients with suspected small bowel disorders as they allow identification of intra- and extra-luminal causes of mechanical occlusion. In large centres, mainly in the USA, SBFT has been superseded by new multidetector-row helical CT, which has been shown to be more effective than SBFT in detecting small bowel obstruction, assessing the gut wall and identifying adhesions from repeated laparotomies (168,169). The involvement of the urinary tract is common in children with PIPO ranging between 36% and 71%, and therefore excretory urograms should also be considered in all patients (2).

5.3 Intestinal Transit Studies

Recommendations:

- The expert group recommends that a contrast study of the small intestine should be routinely used in all patients with a suspicion of PIPO to exclude malrotation and organic lesions occluding the gut. Where available entero- MRI could be used instead or in addition to contrast studies.

LoE: 2

GoR: Moderate

VOTE: 9,9,9,9,9,8,9,8,9,7 (100% agreement, recommendation accepted)

- The expert group recommends that urinary tract ultrasound should be considered in all patients with PIPO to assess the involvement of the urinary tract.

LoE: 2

GoR: Moderate

VOTE: 9,9,9,9,9,9,9,8,7,9 (100% agreement, recommendation accepted)

Practice point:

- SBFT should be performed using water soluble-contrast.

The only paediatric study evaluating the measurement of gut transit time in PIPO through the use of radio-opaque markers was conducted by Heneyke et al (4). All 44 patients showed a delayed whole gut transit time (>96 hours) (4). One case report described its possible utility in identifying the site of functional obstruction in older, cooperative children (170). However, due to the unreliability of small bowel transit, the use of radio-opaque marker studies should be limited to the differentiation between functional constipation and non-retentive faecal incontinence and it should not be routinely recommended in the evaluation of patients with PIPO (171,172).

The most accurate and sensitive measure of gastrointestinal transit is obtained using nuclear medicine. The emptying scan is the most commonly used technique to measure gastric emptying (172). Careful assessment of gastric function may have important implications for management, such as in determining the optimal route of feeding, and in planning the correct type of bowel transplantation (isolated small bowel vs multivisceral). In infants, the meal used is usually milk or formula. A meal containing eggs labelled with technetium 99m is used to evaluate gastric emptying of solids in older children. If solid meals exit the stomach normally, it is unlikely that there is a serious underlying gastric motility disorder (171). One study evaluated the scintigraphic small bowel transit in a subset of children with functional dyspepsia (173). No studies have been conducted in PIPO. In addition, for ethical reasons, normal values have not been validated in children (171,172).

H₂ breath tests use the ingestion of stable isotopes including labelled acetate (liquids) and octanoic acid (solids), and the detection of exhaled carbon-13 carbon dioxide as an indirect measurement of gastric emptying. Both methodologies have shown a good correlation with scintigraphic gastric emptying (174). They represent safe and relatively inexpensive methods of detecting delayed gastric emptying. Their use is not accurate for small bowel emptying in patients with PIPO due to the possible metabolism from small intestine bacterial overgrowth. Recently, Green et al. compared in patients presenting with severe upper GI symptoms the use of the wireless capsule test to gastric emptying measured by scintigraphy and antroduodenal manometry (ADM) (175). Small bowel transit time was defined as the time between the passage of the capsule into the small bowel to when the capsule entered the caecum. The authors demonstrated that the wireless motility capsule test is highly sensitive compared with scintigraphic gastric emptying studies in detecting gastroparesis, and seems to be more sensitive than ADM in detecting motor abnormalities (175). Although a promising tool no study has been conducted using the wireless motility capsule in patients with PIPO to date.

Cine-MRI is a non-invasive, radiation-free diagnostic approach, which has been proposed for assessing and monitoring gastrointestinal motility. Although performed in adult CIPO patients, its role appears attractive for the paediatric population even though general anaesthesia may be required for the younger children therefore hampering an accurate GI motility analysis (176).

Recommendations:

- The expert group does not recommend the use of radio-opaque marker studies for the assessment of small bowel transit in the diagnostic workup of PIPO.

LoE: 5

GoR: Very low

VOTE: 9,7,9,8,5,9,9,9,9,9,8 (92% agreement, recommendation accepted)

- The expert group recommends that the measurement of gastric emptying through the use of scintigraphy should be part of the diagnostic workup of patients with PIPO; the use of C13 breath testing for the indirect measurement of gastric emptying are a reasonable alternative.

LoE: 5

GoR: Very low

VOTE: 8,9,7,9,8,8,9,7,8,5,9,8 (92% agreement, recommendation accepted)

- The expert group does not recommend the use of scintigraphy for the measurement of small bowel and colon transit given that it has not been validated in the paediatric age.

LoE: 5

GoR: Very low

VOTE: 7,8,9,8,8,9,7,7,9,8,9,9 (100% agreement, recommendation accepted)

- The expert group does not recommend the use of H2 breath tests or the wireless motility capsule for the measurement of small bowel transit in PIPO.

LoE: 5

GoR: Very low

VOTE: 9,9,9,9,5,9,7,9,9,9,9,9 (92% agreement, recommendation accepted)

Practice points:

- Radio-opaque marker studies may be used to measure colonic transit.
- Standardized values for paediatric population are lacking.
- H2 breath tests [¹³C]-labelled acetate and octanoic acid for gastric emptying have a good correlation with gastric scintigraphy.
- H2 breath tests are inaccurate for small bowel transit measurement in PIPO due to the possibility the results are influenced by small intestine bacterial overgrowth.

5.4 Manometry

Manometric tests are diagnostic tools, which provide both quantitative and qualitative assessment of oesophageal, intestinal, colonic and anorectal motor function by recording intraluminal

pressure changes within the corresponding organs. The indications, technique, methodology, analysis and clinical utility of the different manometry tests have been described elsewhere (177).

Although in children with PIPO different areas of the GI tract may be involved, the small intestine is virtually always affected. Thus, ADM remains the most discriminating test. In children with PIPO, ADM is indicated in order to confirm the diagnosis, clarify the pathophysiology and optimize clinical management. The identification of a normal fasting pattern, with the presence of normal phase III of the MMC, and the replacement of the MMC cycle by a fed pattern following the ingestion of a test meal are suggestive of a normal neuromuscular function. Hence, an entirely normal recording represents the most useful study in clinical practice as it conclusively rules out the diagnosis of PIPO (178). In children with symptoms suggestive of PIPO and a normal manometric study, conditions such as fabricated illness should be seriously considered (179). Manometry helps to differentiate an enteric neuropathy, in which the motor activity is typically disorganised and/or uncoordinated, from an enteric myopathy, in which the normal manometric patterns are usually preserved, but the amplitude of contractions in both fasting and fed periods do not exceed 20 mmHg (180). However, low amplitude contractions may also reflect the presence of gut dilation, and therefore a confident diagnosis of enteric myopathy should be made only in the absence of dilated loops. The small bowel motor abnormalities described in children with PIPO are reported in Table 5. It is essential to keep in mind that while there is an excellent inter-observer agreement for the number of fasting phase III and their measurement, the inter-observer agreement for the detection of other motor abnormalities is significantly lower (181). There is evidence that ADM also helps to differentiate a pseudo-obstructive syndrome from a mechanical obstruction (at least at the beginning of its presentation) (182) which can be overlooked even by an experienced radiologist, as well as to discriminate between vomiting and rumination (183). This test is useful in assessing the clinical response to the treatment and in predicting the outcome. For instance, it has been shown that it may allow determination of the optimal route for nutritional support (enteral, parenteral), as enteral feedings are more likely to be tolerated in those children with MMC in duodenum or jejunum (184). Similarly, the presence of the phase III of MMC predicts the clinical response to some prokinetics (185). Finally, the presence of

TABLE 5. Antroduodenal manometry features associated with PIPO

Interdigestive or fasting period

- Absence of phase III
- Short intervals between phase III
- Abnormal phase III
 - simultaneous
 - retrograde
- Non migrating burst of contractions*
- Sustained simultaneous cluster of contractions**
- Low amplitude contractions

Postprandial or fed period

- Failure to switch to postprandial period
- Postprandial hypomotility
 - low frequency of contractions
 - low amplitude of contractions
- Non migrating cluster of contractions

*Bursts of contractions are defined as sequences of intense irregular pressure waves not satisfying the definition for phase III of MMC.

**Cluster of contractions are defined as the presence of 3–10 pressure waves of low frequency with higher amplitude and duration than isolated individual contractions.

a myopathic pattern seems to be associated with a poorer outcome in term of survival (186).

Colonic involvement in children with PIPO is very common, as chronic constipation has been described in up to 70% of patients (3). The occurrence of normal high amplitude propagating contractions, spontaneously or after drug stimulation, and an increase in colonic motor activity following a test meal are suggestive of normal colonic neuromuscular function. Colonic motility has been found to be abnormal in most children with PIPO and lower GI symptoms, and a variety of motor abnormalities have been reported, including absent or abnormal high amplitude propagating contractions, impaired gastrocolonic reflex and total absence of colonic contractions (187). In such children, a defunctioning ileostomy decompressing the gut might increase the ability to tolerate enteral feeding (188). Finally, colonic manometry is also indicated before multi-visceral transplantation, in order to assess whether or not the colon should be rescued at the time of transplantation (189).

Oesophageal motor abnormalities have been described in children with PIPO, suggesting that in this group of patients there is a diffuse foregut involvement (14,23). Both neuropathic, such as abnormal propagation of both primary and secondary peristaltic waves, and myopathic abnormalities, such as low amplitude but normally propagated peristaltic waves, have been described. Abnormalities of lower oesophageal sphincter resting pressure and relaxation might be present. Therefore, oesophageal manometry should be performed to assess the extent of disease (150) especially in the presence of dysphagia or abnormal swallow patterns.

Finally, anorectal manometry should be performed in children with PIPO only to rule out Hirschsprung disease and prior to a multi-visceral transplantation.

Recommendations:

- The expert group recommends that antroduodenal manometry should be performed in all children with a presumed diagnosis of PIPO in order to confirm the diagnosis, clarify the pathophysiology and optimise clinical management.

LoE: 2

GoR: Moderate

VOTE: 9,9,7,9,9,6,8,9,9,1,9,7 (92% agreement, recommendation accepted)

- The expert group recommends that in children with suspected or confirmed PIPO, oesophageal, colonic and anorectal manometry may be used to assess the extent of disease. The use of these tests should be directed by clinical presentation.

LoE: 2

GoR: Moderate

VOTE: 9,9,9,9,9,9,9,5,8,9 (92% agreement, recommendation accepted)

Practice point:

An abdominal x-ray taken at the time of the manometric procedure will help determine the correct placement and degree of gut dilation, both of which are of importance for the most accurate interpretation of the manometry tracing.

5.5 Surgery: The Role of Surgery in Diagnosing PIPO and Obtaining Tissue Samples for Histopathology

Surgery has an important role to play in the diagnosis of PIPO (3,4,23). Even in the era of the extremely sophisticated manometric techniques and imaging modalities, surgical exploration may be necessary to definitively confirm or exclude the presence of a mechanical occlusion of the gut (144). Regrettably, data regarding the value of surgery for mere diagnostic purposes in children with PIPO are scarce; furthermore, there is global agreement amongst experts in the field that unnecessary surgeries should be avoided in these patients (3,4,144). This dogma is based on the fact that children with PIPO demonstrate a strong propensity to form dense adhesions after surgery and experience problematic recovery due to prolonged post-surgical paralytic ileus (4).

It is evident, however, that diagnoses that depend on histologic examination of nerve, muscle, and interstitial cells of Cajal (ICC) cannot be made using standard endoscopic biopsies. Thus, tissues studied must be derived from full-thickness, or near full-thickness, biopsies taken with deliberate diagnostic intent or alternatively as the by-product of emergency or planned surgical interventions. On this basis, tissue samples may take the form of deep seromuscular or full-thickness biopsies or resection specimens. If no mechanical obstruction is identified during surgery then intestinal full-thickness biopsies (preferably serial biopsies obtained from both the small and large intestine) should be taken as this may elucidate the pathogenesis of gastrointestinal dysmotility (144).

In children undergoing surgery with therapeutic intent and in whom histopathological analysis has not been performed in the past, tissue is either available (resection) or requires minimal additional risk. In such instances, the benefit of diagnosis (see above) outweighs the risks (although there are no clear data available on this) (3,4,23).

In instances where such surgery is not being performed, but histopathological assessment is deemed helpful, minimally invasive full-thickness biopsy can be performed safely and effectively in children utilising modern laparoscopic surgery techniques (190–195). Although much of this data comes from adults, there are data from children. King et al, 2005 reported 198 colonic seromuscular biopsies with a 1% complication rate (194).

Recommendations:

The expert group recommends that when therapeutic surgery (eg, intestinal resection, ostomy formation, ostomy revision) is performed in children with PIPO, full-thickness intestinal biopsy should be obtained for histopathological analysis.

LoE: 2

GoR: Moderate

VOTE: 9,9,9,9,8,9,7,9,9,9,9 (100% agreement, recommendation accepted)

- The expert group recommends that in patients with PIPO not undergoing therapeutic surgical interventions, full-thickness biopsies may be performed safely with diagnostic intent alone since the benefits probably outweigh the risk.

LoE: 4

GoR: Very low

VOTE: 7,8,7,9,7,7,7,6,7,8,9 (100% agreement, recommendation accepted)

Practice point:

- Laparoscopic surgery represents a safe and effective method to obtain fullthickness intestinal biopsies in children with gastrointestinal motility disorders and can be performed in children who had undergone previous laparotomy.

5.6 Histopathology: Role of Histopathology in the Diagnosis of PIPO

The international guidance published in 2009 (196) evaluated the literature and brought together expert opinion to set acceptable standards of practice for the general pathologist in regard to procurement and preparation of tissue for study, methods of sectioning, and evaluation by routine and other techniques. The working group noted that extraordinary variability existed in histopathologic techniques used for the study of tissues from patients with suspected GI neuromuscular pathology with wide differences in methodologies and expertise continuing to confound the significance and reliability of a variety of reported histopathologic changes in terms of clear delineation from normality. This was highlighted by a survey of practice in which 86 out of 130 European and US histopathology laboratories processed tissue for suspected GI neuromuscular pathology, but only 33 performed more than a single haematoxylin and eosin (H&E) section. Among those that did more specialised tests, none did exactly the same tests (197). This working group reviewed some high quality case control series and used established Delphi consensus methodology to reach the conclusions (not detailed here) underpinning their recommendations. Notably, it should be noted that quantitative assessment of the number of enteric neurons, which may further expand the concept of neuropathy as well as confirm its existence in difficult cases, is not commonly applied in routine pathology because technically difficult. This aspect along with the lack of normative data about enteric neurons may increase the degree of uncertainty about the actual role of histopathology in PIPO. Nonetheless, the challenge for the future will be to have routinely both qualitative and quantitative analysis of histopathology specimens in order to achieve clinically meaningful answers for paediatricians and gastroenterologists dealing with patients suffering from such severe conditions.

It is well acknowledged that the diagnostic yield in PIPO is generally higher than in clinical phenotypes without visceral dilatation, for example, slow-transit constipation, enteric dysmotility. This is particularly true for histopathological findings that are deemed “aetiologic” within “The London Classification,” that is, those defined as “diagnostic of a well-characterised disease with established cause and/or natural history” (198). This observation is stronger for the paediatric populations (199), and especially in congenital onset cases where other confounders are usually absent (198). The PIPO consensus group reviewed the available literature pertaining to paediatric populations. A total of 91 publications included two case control studies (1,200), 30 case series and 25 case reports. A further 7 studies included relevant bench research and there were 29 relevant expert reviews. Specific conclusions based on the available data are not possible due to the poor quality of evidence however a general observation is that the diagnostic yield is high (199) if one ignores issues of selection and publication bias. It is acknowledged that some diagnostic findings have a specificity that is almost absolute in ruling in the diagnosis. Examples

include aganglionosis (201), ganglioneuromatosis, certain neuropathies with inclusions and mitochondrial disorders (202), muscularis propria malformations (203) and severe degenerative (vacuolar) myopathies (31,198,204). On this basis, a sub-recommendation is appropriate for these specific diagnoses.

Regrettably, taking GI neuromuscular disorders as a whole, with the exception of the diagnosis of Hirschsprung disease, there is little published evidence that knowledge of histological diagnosis directly influences clinical care in terms of therapeutic decision-making. This noted, numerous case reports and some small case series suggest a role for immunomodulation in children with specific inflammatory neuropathies (47,205) and myopathies (48,49). Diagnosis may also offer useful prognostic information (for the patient and family including genetic counselling) (4,157,199,203,206,207) or direct other investigations toward secondary aetiology, for example, in mitochondrial disorders (202) and ganglioneuromatosis (208).

Recommendations:

- Histopathological analysis should be performed in centres with expertise to undertake a full panel of neuromuscular labelling techniques in accordance with international guidance. This may require specimen referral to a reference centre.

LoE: 3

GoR: Low

VOTE: 9,9,9,9,9,7,8,7,9,9,9 (100% agreement, recommendation accepted)

- Hirschsprung disease should be excluded.

LoE: 3

GoR: Low

VOTE: 9,9,9,9,9,6,9,9,9,9,9 (100% agreement, recommendation accepted)

Practice points:

- In general, a minimum tissue specimen size of 0.5 x 0.5cm of is required for adequate histopathological analysis however, the adult literature suggests that larger biopsies are ideal, for example, 1.5 x 0.5cm. It is recognised that such biopsy sizes may be difficult to achieve in the very young except at the time of ileostomy formation when the opportunity should be taken to avoid the need for further surgery at a later stage.
- Histopathological diagnosis rarely effects direct treatment decisions, but may provide useful prognostic information and direct further investigation for systemic diseases requiring specific management.

Question 6: Which of the following diagnostic tests should be performed in children with PIPO in order to diagnose an underlying disease?

PIPO may occur as a primary abnormality of the enteric neuromusculature or as a result of a very broad range of systemic

disorders, some potentially curable, that affect GI tract motility. This raises challenges for the understanding of aetiopathogenesis, diagnosis and management in individual cases. Accepting that each child cannot be investigated for every possible cause, this section seeks to clarify the use of investigations to try and exclude/identify secondary causes of PIPO.

6.1: General Laboratory Tests

Laboratory tests are clinically useful to evaluate secondary forms of PIPO (eg, related to systemic diseases), some of which can be potentially curable. In general, a full (complete) blood count, electrolytes, albumin, liver enzymes, fasting cortisol, inflammatory indices may be valuable in all cases (209). Cytomegalovirus, Epstein–Barr virus or other neurotropic viruses, capable of infecting enteric neurons, should be sought in patients with immunodeficiency states (including drug-induced cases) presenting with acquired symptoms of PIPO. Laboratory tests for diabetes mellitus (serum glucose, HbA1C), coeliac disease (tissue Transglutaminase [tTG], Anti-endomysial [EmA] IgA), connective tissue and skeletal muscle disorders (ANA, anti-ds-DNA, SCL-70, creatine phosphokinase, aldolase), and circulating anti-neuronal antibodies might be of aid to clinicians especially in those cases with abrupt onset where an inflammatory/immune-mediated ganglionitis is suspected (with or without a paraneoplastic association) (210). Thyroid function tests (TSH and related free hormone fractions) are mandatory in all cases of severe gut dysmotility associated with symptoms or signs suggestive of hypothyroidism. In certain areas, for example, South America, serology for Chagas disease is recommendable, while urinary porphyrins may be potentially helpful in children with recurrent acute crisis of abdominal pain. Finally, patients receiving total parenteral nutrition (TPN) must be monitored with particular attention to fluids, electrolytes and circulating levels of trace elements.

6.2: Genetics

Most cases of PIPO are sporadic with only few genetic forms identified so far. A number of genes involved in Hirschsprung disease appear not to play a role in PIPO given they are not implicated in autosomal dominant forms. Thus, testing of *GDNF* (glial-cell derived neurotrophic factor), one of its related receptors (*GFRA1*, GDNF receptor- α -1), *EDN3* (endothelin 3) and related receptor (*EDNRB*, endothelin 3 receptor B) does not appear to provide any pathogenetic insight. *SOX10*, however, can be considered an exception to this paradigm. Three patients with a syndromic phenotype of PIPO combined with Waarderburg-Shah features (pigmentary abnormalities and sensorineural deafness) and an underlying “apparently normal” enteric innervation, have been demonstrated to carry de novo heterozygous mutations of *SOX10* (162,163). Other examples include mutations in the following genes: *filamin A* (157), *L1CAM* (211), *actin G2* (40), *thymidine phosphorylase (TYMP)* (212), polymerase γ (*POLG*) (213), *RAD21* (214) and *SGOLI* (215), all identified in recessive forms of PIPO with an associated syndromic phenotype. Although limited by the extreme rarity, syndromic cases require individualised clinical management that includes genetic counselling. A clinician with experience in genetics should be sought in all cases of PIPO associated with other congenital abnormalities and patients with syndromic forms should thus be tested for specific gene/chromosome abnormalities with appropriate molecular approaches. Families may benefit from molecular characterisation of the disease in terms of risk of recurrence and the possibility of prenatal diagnosis where the risk is high.

6.3: Metabolic Screening

Amongst mitochondrial disorders, mitochondrial neuro-gastrointestinal-encephalomyopathy (MNGIE), an autosomal recessive disease due to mutations of the *TYMP* gene (also referred to as endothelial cell growth factor-1, *ECGF1*), has clearly been demonstrated to be characterised by PIPO (216) (Table 3). The earliest onset has been reported at 5 months with an average age at presentation of 18.5 years (217). The mutated gene results in a marked reduction (up to absence) of the encoded thymidine phosphorylase (TP) enzyme leading to a systemic toxic accumulation of nucleosides (ie, thymidine, dThd and deoxyuridine, dUrd), which, in turn, evokes mitochondrial DNA (mtDNA) damage mostly in low-turnover tissues, for example, the gut and skeletal muscle (212,218). In addition to severe gut dysmotility, often heralding the disease, patients with MNGIE manifest cachexia, ptosis, ophthalmoparesis, peripheral neuropathy and exhibit white matter changes (leukoencephalopathy) on magnetic resonance imaging of the brain. A key laboratory finding for addressing the diagnosis is the thymidine phosphorylase activity assay on the buffy coat. This is also a valuable screening test to identify MNGIE cases among patients complaining of severe digestive symptoms (219). Other tests of diagnostic importance include brain magnetic resonance (leukoencephalopathy), and skeletal muscle biopsy (ragged red fibres). Of note, lactic acidosis is not constantly demonstrated. Finally, genetic evaluation, that is, *TYMP* gene mutation analysis, is mandatory to confirm the diagnosis of MNGIE. Apart from *POLG* (DNA polymerase- γ), a form of MNGIE lacking leukoencephalopathy (220), gut dysfunction in other genetic forms of mitochondrial disorders show a clinical phenotype characterized by severe digestive symptoms (eg, constipation or diarrhea with dyspeptic symptoms) but not by recurrent intestinal sub-occlusive episodes.

6.4: Endoscopy

Upper GI endoscopy is useful to exclude a mechanical occlusion of the proximal small intestine, to identify peptic disease presenting with severe upper GI symptoms and to collect duodenal biopsies in cases with suspected coeliac disease or eosinophilic gastroenteropathy. Colonoscopy may, infrequently, be used to exclude mechanical obstruction and for decompression of the large intestine.

6.5: Imaging

Radiology has a role in the exclusion of mechanical obstruction and ultimately of PIPO (see section 5). Intestinal malrotation is present in up to a third of children with PIPO (4). Diverticulosis of the small intestine is an uncommon finding that can be identified in some cases, such as those patients with MNGIE or intestinal pneumatosis. The diagnostic validity of small bowel follow-through is hampered by contrast material flocculation in the dilated intestinal loops filled with sequestered fluids. Thus, examination with contrast medium has been largely replaced by dedicated enterography with high-resolution computerized tomography (CT) (169) or magnetic resonance (MRI), which may be better suited to exclude physical obstruction and assess more accurately intestinal wall adhesions resulting from repeated surgical interventions. Since PIPO can be related to an underlying neuro-myopathy affecting the integrity of the gastrointestinal and urinary systems, radiological evaluations should include urinary tract ultrasound particularly in patients with symptoms suggestive of bladder dysfunction or urinary problems. Review by a urologist should be considered

for further investigations if thought necessary. Finally, imaging of the brain is necessary to identify cases of leukoencephalopathy in forms of PIPO related to MNGIE.

6.6: Autonomic Function Testing

The autonomic nervous system exerts a significant role in the regulation of the visceral function. Disturbances of its function have been identified in patients with gastrointestinal dysmotility including PIPO (39,80,81,83,221).

Available tests for the function of the autonomic system include the following:

- Supine and standing blood pressure as a baseline assessment of the general sympathetic function.
- Responses of the heart rate and blood pressure to the Valsalva manoeuvre which mainly evaluates the sympathetic function and the vagal innervation as well.
- The sudomotor axon reflex test that assesses the postganglionic cholinergic sympathetic function (39).
- Deep breathing test, which evaluates the parasympathetic nerve function (222).
- Orthostatic tilt table test that assesses both the parasympathetic and sympathetic nerve function (223,224).
- Laser doppler perfusion imaging which measures the sympathetic nerve function (225,226).

Autonomic testing should be reserved for patients with signs or symptoms of dysautonomia and manifestations of gastrointestinal dysmotility. Testing can be useful in differentiating an isolated gastrointestinal from a more generalized autonomic disturbance especially when the motility studies are not available or are contraindicated.

6.7: Neurological Evaluation

Diseases of the central and peripheral nervous system can affect the motility of the gastrointestinal system, and at the most extreme end of the spectrum, can result in PIPO (84,132,162,227,228).

The diagnostic tools used to identify underlying neurological deficits include:

- **Imaging** such as:
 - (i) *MRI* (229,230)
 - (ii) *Fluoro-deoxy-glucose positron emission tomography scan* to detect malignancy in patients with suspected paraneoplastic neuropathies and unremarkable conventional radiological findings (231)
- **Serology** (eg, assessment for onconeural antibodies, including anti-Hu, anti-CV2/CRMP-5, anti-ganglionic acetylcholine receptor antibodies, antibodies against voltage-gated potassium channels [VGKC]) (231,232).
- **Histopathology** (eg, muscle biopsy) and **genetic testing** as already described in detail in previous sections (202,213).
- **Electrophysiology** for example, nerve conduction studies (233).

The utilisation of extensive and specialised neurological investigations should be guided by the patients' clinical presentation (symptomatology and findings/signs identified from the clinical examination). Neurological testing can be useful in identifying the underlying pathology that accounts for the patients' clinical presentation.

Recommendations:

The expert group recommends in cases of suspected PIPO to use early in the diagnostic process a minimum battery of diagnostic investigations that are easily performed and directly guide the implementation of the appropriate treatment.

LoE: 4

GoR: Low

VOTE: 9,9,9,9,6,9,9,9,9,9,9 (100% agreement, recommendation accepted)

The expert group recommends to use the following battery of tests:

- full (complete) blood count
- electrolytes, albumin
- renal and liver function tests
- inflammatory indices (ESR and CRP)
- coeliac serology
- fasting cortisol and thyroid function tests
- basic metabolic panel (eg, ammonia, lactate, urinary organic acids)

LoE: 4

GoR: Low

VOTE: 9,9,9,9,7,9,7,9,8,8,9,9 (100% agreement, recommendation accepted)

The expert group recommends that the use of other laboratory investigations, particularly those aimed at identifying secondary causes of PIPO, should be guided by the presence of specific clinical signs and symptoms. Specific attention should be paid to children with suspected PIPO who have one or more of the following:

- Familial history of similar problems
- Deafness
- Cardiac involvement (cardiomyopathy, abnormal conduction or rhythm)
- Neurological symptoms and neurological impairment in the absence of specific cause
- Dermatological involvement (scleroderma, Raynaud phenomenon, palmar erythema, nodules)
- Known or suspected mitochondrial disorders
- Sudden onset of intestinal sub-occlusive episodes (idiopathic or paraneoplastic inflammatory neuro-myo-pathy)

LoE: 4

GoR: Low

Question 7: What is the role of the following management strategies in children with PIPO?

7.1 The Multidisciplinary Team

PIPO has a high number of comorbidities, the most common of which are urinary tract complications, which are present in 33 to 92% of patients and include megacystis, hydronephrosis, urinary retention and urinary tract infections (3,155).

Due to the chronic nature of the disease, invasive procedures, need for surgeries, and frequent presence of chronic pain, the quality of life of patients with PIPO is significantly reduced if compared with healthy patients and children affected by juvenile

rheumatoid arthritis (234). The management of pain should not be limited to the use of narcotics and it often needs to be approached in the context of a multidisciplinary treatment that includes cognitive behavioural interventions (172).

Taking into account comorbidities, nutritional concerns, psychological problems, chronic pain and all the other numerous issues related to PIPO, a multidisciplinary team able to face each single aspect of the disease is strongly recommended for the management of these children (171). The multidisciplinary team is also essential to help identify cases of fabricated or induced illness by carers, previously known as Munchausen by Proxy syndrome, which are still encountered in a small but significant number of children with suspected PIPO.

Recommendations:

The expert group recommends to use a multidisciplinary team approach for the management of PIPO.

LoE: Expert Opinion

GoR: Very low

VOTE: 9,9,9,9,9,9,9,9,9,8,9,9 (100% agreement, recommendation accepted)

Practice point:

The multidisciplinary team should include at least: general paediatrician/adolescent medicine, gastroenterologist, surgeon, nutritionist, psychologist, urologist, geneticist/metabolic medicine specialist, and social worker.

7.2 Nutrition

The role of nutrition in PIPO is of paramount significance as it is well recognised that gut motility improves with optimal nutritional support and declines in the face of under- or malnutrition (235). Optimising nutrition in PIPO, however, is challenging. It requires a dedicated hospital-based nutrition team with a thorough knowledge of all of the available tools. Different strategies, such as oral feeding, enteral feeding (bolus or continuous) or parenteral nutrition (PN), should be tailored to each patient. In the long term, approximately one third of PIPO patients require either partial or total parenteral nutrition, another third requires intra-gastric or -enteral feeding whereas the remaining children are able to tolerate sufficient oral nutrition. However, within all of groups, patients able to tolerate feeds may require some dietary modification in order to maintain enteral nutrition and avoid bezoar formation (eg, use of very low residue ‘bite and dissolve’ feeds, restriction diets, hydrolysed formula). Since long-term PN is associated with a high risk of life-threatening complications maintaining patients on maximally tolerated enteral nutrition is strongly encouraged (236).

In the more severe cases of PIPO, continuous rather than bolus feeds administered via a gastrostomy or jejunostomy may be better tolerated particularly in children with impaired gastric motor function (172,184,237). The expertise required to prescribe PN both at home and in the hospital is usually maximised by the presence of a skilled multidisciplinary team who have a thorough knowledge of energy expenditure, nutrient and element requirements by age and appropriate central catheter handling (238). Long-term PN is life-saving, but it is associated with significant risk of complications, such as central line infections (reported incidence 0.14–0.83 episodes/patient-year on home PN), central venous thrombosis

(reported incidence 0.03 episodes/patient-year) and liver disease (239). There is a significant variation in the reported incidence of both hepatobiliary complications (19%–75%) and advanced liver disease (0%–50%) (239). The main factors contributing to liver injury in these patients are recurrent catheter-related sepsis, small bacterial overgrowth with bacterial translocation, and release of enterotoxins, which also negatively affect liver function, and a paucity of oral and enteral nutrition. A link has been suggested between fat intake and liver disease (240).

Surprisingly, two studies showed no difference in health-related quality of life (HRQoL) in children receiving long-term home PN (HPN) compared to healthy controls (241). Moreover, patient self-reports even exceeded both parent and doctor estimates of HRQoL. In contrast, other studies have reported a lower HRQoL than healthy controls (242,243). The greatest discrepancy in HRQoL between healthy children and children with intestinal failure relates to physical functioning. Patients on HPN have central venous access lines and gastrostomy tubes which interfere with the child's ability to perform age-appropriate physical tasks.

Three studies in children with PIPO showed that the ability to successfully wean from HPN varied between 25% and 38% (244–246). A large French study showed that in these children, neonatal onset, acute onset, urinary tract involvement, and requirement for surgery all predict a low probability of reaching intestinal autonomy (3).

A review on outcome on PN reported that it is a safe treatment with a high probability of survival (247). The survival rate at 1, 5, and 10 years has been reported 90%, 70%, and 60%, respectively (247). The risk of death during HPN is however increased by the absence of a specialist team, and appears greater during the early period of treatment. Moreover, survival probability is decreased in patients who are <2 years, have a very short bowel remnant, presence of a stoma, PIPO of myopathic origin and failure to resume oral feeding (247).

Recommendations:

The expert group recommends to optimise the nutrition for children with PIPO using guidance of a nutritionist as part of a hospital-based multidisciplinary team.

Although the nutrition may comprise parenteral nutrition, management should include strategies to optimise oral and enteral nutrition without compromising intestinal function.

LoE: 4

GoR: Very low

VOTE: 9,9,9,9,9,9,9,9,9,8,9,9,9 (100% agreement, recommendation accepted)

7.3 Drugs/Pharmacotherapy

The therapeutic role of drugs in PIPO patients is mainly limited to the control of intestinal inflammation, suppression of bacterial overgrowth and promotion of GI motility (172,248). Some low-quality reports on different drugs in individual patients and small case series suggest that some molecules may have some beneficial effect. Most of the data on efficacy of different drugs used in patients with CIPO come from adult studies.

In adult studies prokinetics (eg, metoclopramide, domperidone, erythromycin, azithromycin, octreotide, neostigmine, tegaserod) usually combined with antiemetics (eg, promethazine,

ondansetron) have been used in an attempt to improve the GI motor function and reduce the severity of nausea and vomiting (249–252). They have been used in children but this has been limited by variable efficacy and unacceptable extra-intestinal side-effects (eg, metoclopramide, neostigmine) (253).

The use of cisapride for the treatment of CIPO has been reported with some success, with the suggestion it could be considered for patients with acute intestinal pseudo-obstruction when other therapeutic interventions had failed (254). The effect of oral cisapride (10 mg tid) was investigated in a double-blind, placebo-controlled trial in 26 adult patients with upper gut dysmotility: 11 with gastroparesis (8 diabetic, 3 idiopathic) and 15 with CIPO (255). Patients were evaluated at entry and at the end of the 6-week study by upper gastrointestinal manometry and scintigraphic gastric emptying, measurement of body weight, and scoring of a range of symptoms. Cisapride and placebo groups were strictly comparable for all parameters assessed (255). However, cisapride was shown to facilitate gastric emptying in patients with upper gut dysmotility (255). The overall symptomatic benefit during a 6-wk trial of cisapride, 10 mg tid, was not greater, however than that of placebo (255). A number of childhood CIPO studies have reported improved outcomes with the use of cisapride including improved small intestinal motility, decrease in symptoms and improved feed tolerance (185,256). The response to cisapride appeared to be best where there was a presence of propagative contractile activity (185). There is a single report of a child with myopathic CIPO treated with cisapride and subsequently with tegaserod before they were withdrawn from the market (257). In a nationwide Japanese survey of medications used in PIPO, the selective 5HT₄ agent mosapride accounted for 70% of prokinetics used, however limited data was available as to its efficacy (258).

Erythromycin was shown to be effective for relief of acute episodes of ileus and chronic symptoms in some patients with CIPO (259). In one 67-year old patient with CIPO, oral erythromycin (900 mg/d) dramatically improved postprandial abdominal distension, nausea, and vomiting (260). Although erythromycin is successfully used as a gastro-duodenal prokinetic agent, the administration of intravenous erythromycin lactobionate did not induce changes in colonic motility index in 20 children referred for colonic manometry (261).

In 4 patients with CIPO, prucalopride significantly improved a number of CIPO symptoms, especially bloating, nausea and pain (the latter accompanied by a significant decrease in analgesic use) (262). Surprisingly, given the actions of prucalopride in chronic constipation, stool consistency and frequency, and laxative use were not altered. Hence, the underlying mechanism remains unclear, and could at least partly be based on actions of prucalopride in the proximal gastrointestinal tract (262).

Intravenous administration of neostigmine was reported to have reversed an acute colonic pseudo-obstruction (263). Intravenous administration of neostigmine was reported to have reversed an acute colonic pseudo-obstruction (263). Seven (adult) patients with CIPO had some improvement with pyridostigmine of symptoms with few side effects (264). In children there are reports of the efficacy of neostigmine. Ten children (3–14 years of age) with hematologic malignancies and diagnosed with acute colonic pseudo-obstruction received 0.01 mg/kg per dose (maximum 0.5 mg) twice daily for a maximum of 5 total doses (246). Eight patients showed therapeutic response to neostigmine at a median of 29 hours after the initial administration (range, 1–70). One patient experienced diplopia, and another experienced aggravated abdominal pain after neostigmine infusion but neither of these patients complained of cardiovascular symptoms that required treatment.

The somatostatin analogue octreotide has been proposed as a possible therapeutic agent in patients with abnormal gastrointestinal

motility (265). In children with chronic bowel disorders, subcutaneous octreotide induced phase IIIs that differed from spontaneous phase IIIs and were not inhibited by meals. Octreotide decreased antral motility during fasting and inhibited intestinal phase II. Octreotide was studied in 23 children, 8 with PIPO, 6 with non-ulcer dyspepsia, 6 with gastro-oesophageal reflux disease, and 3 with intractable constipation. After recording fasting motility for more than 4 hours, the children were randomised to receive 0.5 or 1 µg/kg of subcutaneous octreotide. Motility was recorded for another hour after feeding in 12 children (265). Phase III of the motor migrating complex was present in 13 of 23 children before and in 21 after octreotide ($P < 0.02$) (265). Feeding abolished the inhibitory effect of octreotide on antral motility (265). In a recent study, the use of octreotide in children with PIPO was associated with improved enteral feed tolerance, which appeared to correlate both with the presence of octreotide-induced intestinal phase III of the migrating motor complex as well as a higher median increase in intestinal motility index (266).

Acute administration of lubiprostone, a selective type-2 chloride channel (ClC-2) activator, in dogs at a dose of 48 µg accelerated GI motility and enhanced GI contractions in the postprandial state (267). These findings suggest that lubiprostone may have an indirect prokinetic effects on the GI tract and vagal activity may be involved (267). To date no studies have been performed evaluating the effect of lubiprostone in children with PIPO.

Transdermal buprenorphine was shown to alleviate intractable abdominal pain in 4 children with PIPO (268). Dextroamphetamine sulfate in combination with L-thyroxine decreased abdominal pain in a 23-year-old patient with CIPO (269).

A 34-year-old man with MELAS (mitochondrial myopathy, encephalopathy, lactic acidosis, and stroke-like episodes) showed also episodes of CIPO, improved by the administration of distigmine bromide (270).

Dai-kenchu-to (DKT), a traditional Japanese herbal medicine (Kampo medicine), composed of zanthoxylum fruit, ginseng root, dried ginger rhizome and malt sugar, is clinically effective for postoperative ileus and chronic constipation (271). In a description of its use in 2 cases DKT was found to be effective in a case of megacystis-microcolon-intestinal hypoperistalsis syndrome, but not in one with CIPO (271). A recent nationwide survey in Japan regarding pharmacotherapy in patients with PIPO revealed widespread use of conventional and traditional pharmaco-therapeutic agents including prokinetics, probiotics, laxatives and Japanese herbal (Kampo) medicines (258).

Although there is little evidence for the use of probiotics, emerging pilot studies have explored the use of faecal microbiota transplantation in CIPO with reports of improved symptoms, indirect markers of intestinal obstruction and small intestinal bacterial overgrowth (272).

CONCLUSION

Overall, there is no recommended drug treatment to improve GI motility in the majority of patients with PIPO. A trial of medications could be tried in PIPO at the discretion of the specialist caring for the patient (Table 6). Buprenorphine may alleviate pain and in order to try to stimulate motor activity, erythromycin, pyridostigmine and octreotide are effective in some children. The best studied and tested prokinetics, that is, cisapride and tegaserod, have been withdrawn from the market due to safety concerns. The need for new prokinetics drugs (since lubiprostone is not a “true” prokinetic) with increased safety and efficacy has resulted in new products (eg, prucalopride, lubiprostone, aprepitant, ghrelin), but there is no data on their use in PIPO.

TABLE 6. Prokinetic medications that could be tried in PIPO at the discretion of the specialist caring for the patient (Important: suggested doses only. Before use need to check with local formulary and dosing guidelines)

DRUG	DOSAGE	MECHANISM	SIDE EFFECT
Amoxicillin/ Clavulanate	20 mg/kg up to antibiotic dose		Hepatitis, nausea, vomiting, diarrhoea, headache, dizziness.
Azithromycin	10 mg/kg once daily	Motilin receptor agonist	Anorexia, arthralgia, dizziness, headache, dyspepsia, paresthesia, reversible hearing loss, anxiety, hypoaesthesia.
Bethanecol	0.1–0.2 mg/kg per dose before meal. Adult dose: 10–50 mg 4 times daily	Cholinergic acting on muscarinic receptor	Bronchial constriction, urinary frequency, miosis, lacrimation, flushing.
Cisapride	0.2–0.3 mg/kg per dose 3–4 times daily 30 min before a meal.	5HT ₄ agonist with Acetylcholine release in the gut; 5HT ₃ antagonism; <i>ether-a-go-go</i> potassium (hERG) channel	QTc interval prolongation, diarrhoea, abdominal pain, headache. Available only on compassionate use. Contraindicated with cytochrome P4503A4 inhibitors.
Domperidone	0.1–0.3 mg/kg per dose 2–4 times daily 30 min before a meal. Max dose 10 mg 3–4 times daily	Dopamine-2 (D ₂) receptor antagonist. Peripheral action (gut). Unable to cross blood-brain barrier	Diarrhoea, QTc interval prolongation. Hyperprolactinemia.
Erythromycin	3–5 mg/kg per dose. Adult dose: 50–250 mg 3–4 times daily	Motilin receptor agonist	Nausea, vomiting, abdominal pain. Contraindicated with cytochrome P4503A4 inhibitors.
Metoclopramide	0.4–0.8 mg/kg per day 3–4 times daily 30 min before a meal. Max dose 10 mg 3–4 times daily	Dopamine-2 (D ₂) receptor antagonist at CTZ, 5HT ₄ agonist in the gut. Able to cross blood-brain barrier	Acute extrapyramidal reaction, dyskinesia with long term-use. Sedation. Hyperprolactinemia.
Neostigmine	0.01–0.05 mg/kg per dose (i.v, repeated at suitable intervals, max 5 dose reported). Adult 1 mg single dose	Acetylcholinesterase inhibitor	Abdominal pain, diarrhoea, nausea, vomiting, increased salivation, bradycardia, wheezing.
Octreotide	0.5–1/kg µg subcutaneous once daily	Somatostatin analogue	Arrhythmia, hyperglycemia, biliary colic, headache, hepatitis, decreased gastric motility (suggest combined use with erythromycin), pancreatitis (abrupt suspension).
Prucalopride	0.02–0.04 mg/kg per day max 2 mg/daily	5HT ₄ agonist with Acetylcholine release in the gut	Headache, nausea, diarrhoea, abdominal pain.
Pyridostigmine Bromide	Start with 0.1–0.3 mg/kg per dose 2–3 times daily and increase as tolerated	Acetylcholinesterase inhibitor	Abdominal pain, diarrhoea, nausea, vomiting, increased salivation, bradycardia, wheezing.

Recommendations:

- The expert group is unable to recommend to use a specific medication for the treatment of PIPO

LoE: 4

GoR: Very low

VOTE: 9,9,9,9,8,9,8,9,8,9,8,9 (100% agreement, recommendation accepted)

- The expert group recommends that the use of medications, probiotics and faecal microbiota transplantation for the treatment of PIPO be restricted to

specialised centres. The evidence for efficacy is too limited and the adverse effects of some treatments too frequent to be recommended as therapeutic approach applied in non-specialised centres.

LoE: 4

GoR: Very low

VOTE: 9,9,9,9,8,9,9,9,8,8,9 (100% agreement, recommendation accepted)

Practice Points

A trial of medications could be tried in PIPO at the discretion of the specialist caring for the patient (Table 6)

7.4 Surgery

Surgery has a pivotal role in the management of children with PIPO but only interventions deemed to be absolutely necessary should be performed in children with PIPO given the potential increased risk of adhesions with each procedure along with prolonged ileus and potentially the further deterioration of bowel function (4).

Classical surgical techniques focus on the provision of access to the stomach and small bowel in the form of a gastrostomy or enterostomy (ie, jejunostomy, ileostomy). Such ostomies may provide a convenient route for enteral alimentation and/or allow for adequate gastrointestinal decompression. Novel surgical approaches include the implantation of devices that deliver electrical stimulation to the gastrointestinal musculature (273,274). None of the above treatments is curative. Intestinal transplantation (either isolated small bowel or multiviscera) remains today the only definitive cure for children with PIPO and is addressed in the next section (144).

The main goals of creating a gastrostomy and/or jejunostomy in patients with PIPO are to establish a convenient and durable method of gastrointestinal decompression, enteral feeding and administration of medications. Indeed, these procedures have been shown to reduce the degree of abdominal distension, frequency of vomiting and number of hospitalisations in children with PIPO, and in turn promote an improved overall quality of life (2–4,181, 275,276).

In patients with PIPO who experience recurrent pseudo-obstructive episodes or in whom enteral feeding is not tolerated, the formation of a defunctioning enterostomy (ileostomy or colostomy) is almost uniformly beneficial. A decompressive enterostomy has been shown to alleviate obstructive symptoms in approximately 50% of PIPO patients (2–4,23,276). Reducing the stasis of intestinal contents and gaseous distension offers a chance to preserve already compromised intestinal motor function and establish a more acceptable intestinal transit. Ultimately, this should increase the tolerance of enteral feeding and consequently reduces reliance on PN (277). It is advisable to decompress the small intestine early in the course of the disease to best preserve motor function of the gut and limit further deterioration/decompensation) (4).

The anatomical level of the defunctioning enterostomy is still a matter of debate, but an ileostomy appears to offer the highest rate of symptom relief (4). In a significant number of patients initially managed with a colostomy, an ileostomy was ultimately created because of persistent symptomatology with improved effect (4,277). Even for children in which the decompressive enterostomy fails to effectively reduce the degree of dependence on parenteral nutrition, it may still be beneficial by decreasing bacterial overgrowth and potential translocation and thus diminishing the risk of septic episodes (277). Enterostomy-associated complications, however, are not insignificant in PIPO patients. There is an increased risk of stomal prolapse along with intestinal necrosis (278). A meticulously constructed ileostomy combined with careful management of the ostomy, reduces the probability of prolapse thus minimizing the risk of additional intestinal resection (4,278).

Small bowel resections should be avoided as their efficacy and safety are not well-established in PIPO (279). Moreover, they may contribute to short gut syndrome and intestinal failure-associated liver disease (276,280,281). One additional concern is that resections of small intestine may decrease the abdominal domain required to optimise the outcome of any future intestinal transplantation (276,280).

Surgical procedures aiming to lengthen and reduce the calibre of dilated intestinal segments (eg, longitudinal intestinal lengthening and tailoring, serial transverse enteroplasty) have

shown promising results in children with intestinal failure, including patients with PIPO (238).

Clinicians should be vigilant about possible volvulus in PIPO especially where there has been acute onset of abdominal distension and pain, given that delay in diagnosis can result in complications such as intestinal ischemia and perforation (282–284).

Closure of the decompressive ileostomy and restoration of the gut continuity may be attempted in carefully selected patients who have demonstrated significant and clear improvement post ileostomy formation, have managed to wean off PN and remain on full enteral and/or oral feeds without experiencing significant troublesome symptoms for a prolonged period of time. In such patients, an ileo-rectal Duhamel pull-through has proven to be the most effective approach. Indeed, approximately 66% of children managed this way remained asymptomatic and off parenteral nutrition (3,4,277,281). Reversal of ileostomies appears most likely to succeed in neuropathic PIPO especially where there is evidence of propagative motor activity (4) (Thapar et al; unpublished observations).

Novel surgical methods involve the implantation of devices to provide electrical pacing to the gastrointestinal musculature (285,286). This technique is still in its infancy and more studies are required to draw definitive conclusions regarding its applicability, efficacy and safety in PIPO patients.

Recommendations:

- The expert group recommends to consider the formation of a venting / feeding gastrostomy and/or jejunostomy in all patients with PIPO.

LoE: 2

GoR: Moderate

VOTE: 8,9,9,9,9,3,9,9,7,6,8,9 (92% agreement, recommendation accepted)

- The expert group recommends to consider the formation of a decompressive ileostomy in all patients with PIPO on parenteral nutrition.

LoE: 2

GoR: Moderate

VOTE: 9,9,9,9,9,3,9,9,7,4,8,9 (83% agreement, recommendation accepted)

- The expert group recommends that the number of surgical interventions in PIPO patients should be minimised in order to avoid potential complications (eg, adhesion formation, prolonged paralytic ileus post-surgery) and diagnostic uncertainty regarding the pseudoobstructive or true occlusive nature of future obstructive episodes.

LoE: 2

GoR: Moderate

VOTE: 9,9,9,9,9,9,9,9,9,9,9 (100% agreement, recommendation accepted)

- The expert group recommends that small intestinal resections should be avoided in order to prevent the occurrence of short bowel syndrome and intestinal failure-associated liver disease and to prevent reduction of the abdominal domain in the view of potential future intestinal transplantation.

LoE: 2

GoR: Moderate

VOTE: 9,9,7,9,9,9,9,9,9,9,9 (100% agreement, recommendation accepted)

Practice points:

- Surgery for children with a known diagnosis of PIPO should (where possible) be restricted to centres and practitioners with experience in managing such children
- The gastrostomy and jejunostomy can be used for gastrointestinal decompression, enteral feeding and administration of medications.
- When surgery is indicated, a gastrostomy tube insertion can be achieved during the same procedure.
- If considered, a surgically placed jejunostomy may be superior in terms of functionality compared to a gastrojejunostomy.
- Ostomies may be utilised to perform motility investigations (manometries) by serving as insertion sites for the manometry catheters.

7.5 Intestinal Transplantation?

Intestinal transplantation still remains today the only definitive cure for PIPO (144). The outcomes and survival rates in experienced centres have improved (up to 60% survival at five years) during the last decade owing to advances in both the surgical approach (eg, multi-visceral transplantation) and immunosuppressive treatment (238,287–292). Other novel therapeutic modalities, still in their infancy and that target specific PIPO subgroups, may provide future potential (293). Intestinal transplantation should be considered as a therapeutic option in patients with PIPO suffering from TPN-associated complications (IFALD-intestinal failure associated liver disease, central venous catheter-related thrombosis, recurrent episodes of central line sepsis) and/or poor quality of life with high risk of morbidity and mortality (frequent pseudo-obstructive episodes necessitating repeated hospitalizations) (277,288–292,294,295).

Undoubtedly, a multidisciplinary approach (eg, paediatric gastroenterologist and/or hepatologist, paediatric surgeon, dietitian, urologist, psychologist, social worker etc.) is crucial for the favourable outcome of any intestinal rehabilitation/intestinal transplantation program. The multidisciplinary team at the referring centre needs to recognise complications and apply all medical/surgical/vascular access strategies to prevent the recurrence and progression of complications particularly the development of IFALD. Once complications develop, such as IFALD with serum bilirubin > 100 µmol/L sustained over a period of 3 to 4 weeks, referral to an intestinal transplant centre is recommended to assess suitability for transplant (277,288–292,294,296–298).

The intestinal transplant assessment should include a detailed assessment of intestinal function, severity of IFALD and assessment of vascular access sites as per the individual centre protocol. In addition, careful consideration should be given to the assessment of the following in children with PIPO: (1) narcotic usage in children with PIPO. A clear strategy to wean children from narcotic usage in the post-transplant period with psychological and behavioural therapeutic interventions should be instituted in the pre-transplant period, and continued into the post-transplant

period. (2) Careful evaluation of kidney function at the intestinal transplant assessment is essential. Pre-existing urological problems in children with PIPO may have an adverse effect on kidney function. If the kidney function is severely affected, a kidney may be included as a part of the multi-visceral graft. If kidney function is mildly affected, the immunosuppression in the post-transplant period should be tailored to a renal sparing protocol so as to minimize damage to the kidneys in the post-transplant period. Families should be counselled about the increased risk of urinary tract infections in the post-transplant period particularly in children with pre-existing bladder problems who practice intermittent urinary catheterisation. (3) A detailed assessment of the motility function of the foregut may aid in guiding the type of intestinal transplant to be done, that is, inclusion of the stomach. (4) A detailed assessment of the past line infections should be obtained to identify the antibiotic policy in the pre and post-transplant period. Intravenous antibiotic line locks, ethanol locks or taurolodine line locks should be used depending on the individual central line infection prevention policy when the child is on the transplant waiting list (187,189).

Overall, four types of intestinal transplant can be performed

- (i) Isolated intestinal transplant: normal foregut motility and none or mild IFALD
- (ii) Combined liver and bowel transplant: normal foregut motility and moderate to severe IFALD
- (iii) Modified multi-visceral transplant, that is, inclusion of stomach, duodenum and pancreas along with the small intestine +/- large intestine: abnormal foregut motility and none or mild IFALD
- (iv) Multi-visceral transplant – that is, inclusion of stomach, duodenum, pancreas and liver along with the small intestine +/- large intestine: abnormal foregut motility and moderate to severe IFALD

As per the intestinal transplant registry, amongst the various conditions needing intestinal transplantation, children with motility disorders constitute the second commonest group (18%). Amongst gut motility disorders PIPO is the most frequent clinical entity requiring small intestinal transplantation often in conjunction with liver due to end-stage IFALD (277,299,300).

The outcomes and survival rates in experienced centres have improved 60% survival rate at five years) during the last decade owing to advances in both surgical approaches (eg, multi-visceral transplantation) and immunosuppressive treatments (238,287–292,301–303).

Recommendations:

- The expert group recommends that intestinal transplantation (either isolated small bowel or multi-visceral) should be considered in patients with PIPO presenting with life threatening TPN-associated complications such as intestinal failure associated liver disease (IFALD), central venous catheter-related thrombosis, recurrent episodes of central line sepsis, loss of central line access) and/or poor quality of life with high risk of morbidity and mortality (frequent pseudo-obstructive episodes necessitating repeated hospitalisations, difficult fluid electrolyte imbalance due to excessive fluid shifts).

LoE: 2

GoR: Moderate

VOTE: 8,8,8,9,9,9,8,9,9,8,9 (100% agreement, recommendation accepted)

- The expert group recommends, in patients with PIPO where intestinal transplantation is a likely possibility, early discussion with the transplant centre combined with a multidisciplinary approach to decide about the optimal timing of assessment for intestinal transplantation.
- LoE: 2
- GoR: Moderate

VOTE: 9,9,8,9,9,9,8,9,9,9,7 (100% agreement, recommendation accepted)

Question 8: What are the outcomes and prognosis of PIPO and what factors contribute to these?

OUTCOME AND PROGNOSIS

Complications

Stoma prolapse (278), recurrent pancreatitis (151), diversion colitis (304) and excessive fluid losses with high ileostomy output (305) have been reported in patients with CIPO. In patients with gastric and upper digestive tract involvement, gastric perforation and gastric bezoars may occur (3).

Specific genetic mutations are associated with complications. In Multiple Endocrine Neoplasia type 2B a specific germ-line point mutation in the RET gene occurs in 95% of patients (306). About 40% of patients have diffuse ganglioneuromatosis of the gastrointestinal tract, causing obstructive symptoms. All affected individuals with the M918T RET mutation are at risk for early development of a very aggressive form of medullary thyroid cancer (307). Early prophylactic thyroidectomy should be considered in these cases (308). In cases with cardiac involvement (SGOL1), a pacemaker is indicated since severe bradycardia may occur (215). Filamin A gene on chromosome X as well as thymidine phosphorylase mutations are both associated with seizures and impaired neurological development (157).

Psychological consequences of the disease on the patient and repercussion on the family may be extremely important and must be taken into account in the management. There is minimal data on psychological or psychiatric co-morbidities or consequences has been specifically published in children (234).

Outcome

In secondary and acquired forms of PIPO, outcome is dependent upon the underlying disease responsible for the dysmotility. In cases of destruction of enteric innervation or musculature, deterioration may occur rapidly without specific treatment (205). Most often viral infections resolve spontaneously (309,310).

In primary forms of PIPO, the prognosis is guarded. In one series of 105 patients, two thirds required parenteral nutrition and 41% could not be enterally fed. More than half of the patients were PN-dependent for periods ranging from 2 months up to 16 years. Eleven patients (10%) received PN for more than 10 years. Twenty-four of the 58 patients who underwent bypass surgery were able to eat normally and twenty of those eventually had their stoma closed

(3). Henyke and colleagues reported that if PN is required for more than 6 months, the child will probably be PN-dependent for at least four years (4).

Mortality

Progress in the management of parenteral nutrition and the use of bowel decompression have reduced the high mortality rate reported in historical series in neonates, among whom up to 90% of patients died before 1 year of age (108,142). In series published more recently, mortality varied from 4.8% to 32% (2,4,5).

Underlying PIPO is rarely the cause of death except in cases with MEN2B and medullary carcinoma. In paediatric series reported to date, the high mortality rate is almost always due to iatrogenic complications. Long-term TPN-related complications, including central venous catheter associated-sepsis and liver failure, and post-transplantation complications are the major contributing factors to mortality and morbidity in patients with PIPO (2–4). Sudden cardiac arrest has been reported in two patients with PIPO (311).

Prognostic factors

In the largest paediatric series published to date, comparison between patients requiring and those no longer requiring artificial feeding showed significant clinical differences in terms of likelihood of neonatal onset, urinary tract involvement, requirement for surgery during the course of the disease and myopathic disorders, all features which were more frequent in cases with a poor prognosis (2–4). The presence of the phase III of the MMC has been reported by several groups to be a favourable prognostic indicator for tolerance of enteral feeding (150,184) response to cisapride (185) and mortality (186).

Recommendations:

- Stoma prolapse, recurrent pancreatitis, diversion colitis and electrolyte and fluid imbalance are the most common complications.
- In primary PIPO, TPN is required in almost half of the patients for a variable period of time (up to several years).
- In secondary and acquired forms, the outcome is related to the underlying cause.
- Although life expectancy has significantly improved, TPN-related complications, and post-transplantation complications are currently the major contributing factors to mortality and morbidity in PIPO patients.
- Poor prognosis is mainly related to the neonatal onset, phenotype (myopathic involvement), multiple surgeries and absence of phase III of the MMC on ADM.

Question 9: What is the optimal transition to adult life and clinical care for children with PIPO?

As detailed above, the advent of PN and improvements in clinical care have now seen many cohorts of children with PIPO surviving into early adulthood. Very little literature exists, however, regarding the optimal transition of PIPO to adult services (312,313).

Recommendations:

- The expert group recommends that children with PIPO should be transitioned to specialist adult gastroenterology centres with appropriate expertise in neurogastroenterology and motility as well as intestinal failure and parenteral nutrition (including home PN).

LoE: Expert Opinion

GoR: Very low

VOTE: 9,9,8,9,7,9,9,9,8,9,9 (100% agreement, recommendation accepted)

- The expert group recommends that transition should commence by the age of 15 years and initially involve both the paediatric and adult gastroenterology consultants as well as local GI expertise

LoE: Expert Opinion

GoR: Very low

VOTE: 9,9,5,9,6,9,7,8,6,6,9,9 (92% agreement, recommendation accepted)

Question 10: What clinical questions and research agenda should be addressed for PIPO in the future?

It is clear that PIPO presents considerable challenges from developing a basic understanding of the aetiopathogenesis to optimal strategies for diagnosis and management. In order to drive progress and improve what are current poor outcomes in PIPO, a concerted and multidisciplinary effort is needed. Given the rarity of the condition it is likely the initial step should include the development of national referral centres for the diagnosis and management of PIPO as well as national or international registries/databases. Such registries/databases will not only help inform epidemiology (incidence, geographical distribution, patient demographics etc.) of PIPO but lay the path for networks to exchange clinical information and samples including the formation of tissue banks for genetic and multi-omic analyses. Most importantly, the development of referral centres will need to be supported by managed clinical (shared

care) networks that are able to support the care of complex PIPO patients closer to home.

There is no doubt that the coming decade will lead to the advent of more accurate diagnosis of PIPO and combined with basic science techniques will achieve an improved understanding of aetiopathogenesis. This combinatorial approach must be encouraged and most likely will flourish within established clinical academic centres or collaborations. Ultimately, this technology may lead, as it has done with oesophageal high-resolution manometry, to better mapping of function, less variability in analysis, interpretation and ultimately management.

With progress in aetiopathogenesis and diagnosis the term PIPO itself is likely to need to be qualified in the future with more emphasis on precise subtypes. This classification will enhance, and is arguably essential for, trials to inform optimal medical and surgical treatments. It would avoid blunderbuss approaches to the management of PIPO and allow clinical trials on novel medications, therapies and nutritional support with potential beneficial effect on GI motility as well as surgical considerations, for example, optimal level for ostomy formation to minimise pseudo-obstructive episodes without risking “short-bowel syndrome.”

Recommendations:

The expert group recommends the formation of national referral centres for the diagnosis and management of PIPO.

LoE: Expert Opinion

GoR: Very low

VOTE: 9,9,9,9,9,6,9,9,8,9,8 (100% agreement, recommendation accepted)

The expert group recommends the formation of national or international multidisciplinary collaborations addressing clinical and basic science research into the aetiopathogenesis, diagnosis and management of PIPO.

LoE: Expert Opinion

GoR: Very low

VOTE: 9,9,9,8,9,8,9,8,9,9,9 (100% agreement, recommendation accepted)

Recommendation Table

The expert group recommends that/the

- CIPO occurring in infants and children be considered a separate entity from that in adults and be referred to as PIPO
- a uniform definition be applied to Paediatric Intestinal Pseudo-Obstruction
- uniform diagnostic criteria be used for the definitive diagnosis of Paediatric Intestinal Pseudo-Obstruction
- development of robust national and international registries for PIPO in order to better delineate the epidemiological characteristics of PIPO.
- a diagnosis of PIPO should be suspected in the following situations:
 - In all children presenting with symptoms of intestinal obstruction without an occluding lesion.
 - In neonates with:
 - Prenatal diagnosis of megacystis/enlarged bladder
 - Persistent or recurrent obstructive symptoms after exclusion of Hirschsprung disease and hypothyroidism.
 - Persistent vomiting after a Ladd procedure for malrotation
 - Symptoms of intestinal obstruction associated with bladder dysmotility
 - In infants or children with:
 - Persistent or recurrent obstructive symptoms after exclusion of Hirschsprung disease
 - Persistent vomiting/intestinal obstruction after correction of malrotation
 - Symptoms of intestinal obstruction associated with
 - Ptoisis
 - Deafness
 - Abnormal cardiac rhythm / function

6. abdominal radiography should be routinely used in all patients with a suspicion of PIPO as first screening to identify dilated small intestinal loops.
7. a contrast study of the small intestine should be routinely used in all patients with a suspicion of PIPO to exclude malrotation and organic lesions occluding the gut. Where available entero-MRI could be used instead or in addition to contrast studies.
8. urinary tract ultrasound should be considered in all patients with PIPO to assess the involvement of the urinary tract.
9. radio-opaque marker studies should not be used for the assessment of small bowel transit in the diagnostic workup of PIPO.
10. measurement of gastric emptying through the use of scintigraphy should be part of the diagnostic workup of patients with PIPO; the use of C13 breath testing for the indirect measurement of gastric emptying are a reasonable alternative.
11. scintigraphy should not be used for the measurement of small bowel and colon transit given that it has not been validated in the paediatric age.
12. H₂ breath tests or the wireless motility capsule should not be used for the measurement of small bowel transit in PIPO.
13. antroduodenal manometry should be performed in all children with a presumed diagnosis of PIPO in order to confirm the diagnosis, clarify the pathophysiology and optimise clinical management.
14. oesophageal, colonic and anorectal manometry may be used to assess the extent of disease in children with suspected or confirmed PIPO. The use of these tests should be directed by clinical presentation.
15. when therapeutic surgery (eg, intestinal resection, ostomy formation, ostomy revision) is performed in children with PIPO, full-thickness intestinal biopsy should be obtained for histopathological analysis
16. in patients with PIPO not undergoing therapeutic surgical interventions, full-thickness biopsies may be performed safely with diagnostic intent alone since the benefits probably outweigh the risk.
17. Histopathological analysis should be performed in centres with expertise to undertake a full panel of neuromuscular labelling techniques in accordance with international guidance. This may require specimen referral to a reference centre.
18. Hirschsprung disease should be excluded.
19. in cases of suspected PIPO to use early in the diagnostic process a minimum battery of diagnostic investigations that are easily performed and directly guide the implementation of the appropriate treatment.
20. to use the following battery of tests:
 - i. full (complete) blood count
 - ii. electrolytes, albumin
 - iii. renal and liver function tests
 - iv. inflammatory indices (ESR and CRP)
 - v. coeliac serology
 - vi. fasting cortisol and thyroid function tests
 - vii. basic metabolic panel (eg, ammonia, lactate, urinary organic acids)
21. the use of other laboratory investigations, particularly those aimed at identifying secondary causes of PIPO, should be guided by the presence of specific clinical signs and symptoms. Specific attention should be paid to children with suspected PIPO who have one or more of the following:
 - a. Familial history of similar problems
 - b. Deafness
 - c. Cardiac involvement (cardiomyopathy, abnormal conduction or rhythm)
 - d. Neurological symptoms and neurological impairment in the absence of specific cause
 - e. Dermatological involvement (scleroderma, Raynaud phenomenon, palmar erythema, nodules)
 - f. Known or suspected mitochondrial disorders
22. to use a multidisciplinary team approach for the management of PIPO.
23. to optimise the nutrition for children with PIPO using guidance of a nutritionist as part of a hospital-based multidisciplinary team. Although the nutrition may comprise parenteral nutrition, management should include strategies to optimise oral and enteral nutrition without compromising intestinal function.
24. it is unable to recommend to use a specific medication for the treatment of PIPO
25. the use of medications, probiotics and faecal microbiota transplantation for the treatment of PIPO be restricted to specialised centres. The evidence for efficacy is too limited and the adverse effects of some treatments too frequent to be recommended as therapeutic approach applied in non-specialised centres.
26. to consider the formation of a venting / feeding gastrostomy and/or jejunostomy in all patients with PIPO.
27. to consider the formation of a decompressive ileostomy in all patients with PIPO on parenteral nutrition.
28. the number of surgical interventions in PIPO patients should be minimised in order to avoid potential complications (eg, adhesion formation, prolonged paralytic ileus post-surgery) and diagnostic uncertainty regarding the pseudo-obstructive or true occlusive nature of future obstructive episodes.
29. small intestinal resections should be avoided in order to prevent the occurrence of short bowel syndrome and intestinal failure-associated liver disease and to prevent reduction of the abdominal domain in the view of potential future intestinal transplantation.
30. intestinal transplantation (either isolated small bowel or multi-visceral) should be considered in patients with PIPO presenting with life threatening TPN-associated complications such as intestinal failure associated liver disease (IFALD), central venous catheter-related thrombosis, recurrent episodes of central line sepsis, loss of central line access) and/or poor quality of life with high risk of morbidity and mortality (frequent pseudo-obstructive episodes necessitating repeated hospitalisations, difficult fluid electrolyte imbalance due to excessive fluid shifts).
31. in patients with PIPO where intestinal transplantation is a likely possibility, early discussion with the transplant centre combined with a multidisciplinary approach to decide about the optimal timing of assessment for intestinal transplantation.
32. children with PIPO should be transitioned to specialist adult gastroenterology centres with appropriate expertise in neurogastroenterology and motility as well as intestinal failure and parenteral nutrition (including home PN).
33. transition should commence by the age of 15 years and initially involve both the paediatric and adult gastroenterology consultants as well as local GI expertise
34. formation of national referral centres for the diagnosis and management of PIPO.
35. formation of national or international multi-disciplinary collaborations addressing clinical and basic science research into the aetiopathogenesis, diagnosis and management of PIPO.

REFERENCES

- Amiot A, Cazals-Hatem D, Joly F, et al. The role of immunohistochemistry in idiopathic chronic intestinal pseudoobstruction (CIPO): a case-control study. *Am J Surg Pathol* 2009;33:749–58.
- Mousa H, Hyman PE, Cocjin J, et al. Long-term outcome of congenital intestinal pseudoobstruction. *Dig Dis Sci* 2002;47:2298–305.
- Faure C, Goulet O, Ategbo S, et al. Chronic intestinal pseudoobstruction syndrome: clinical analysis, outcome, and prognosis in 105 children. French-Speaking Group of Pediatric Gastroenterology. *Dig Dis Sci* 1999;44:953–9.
- Heneyke S, Smith VV, Spitz L, et al. Chronic intestinal pseudo-obstruction: treatment and long term follow up of 44 patients. *Arch Dis Child* 1999;81:21–7.
- Muto M, Matsufuji H, Tomomasa T, et al. Pediatric chronic intestinal pseudo-obstruction is a rare, serious, and intractable disease: a report of a nationwide survey in Japan. *J Pediatr Surg Int* 2014;49:1799–803.
- Di Nardo G, Di Lorenzo C, Lauro A, et al. Chronic intestinal pseudo-obstruction in children and adults: diagnosis and therapeutic options. *Neurogastroenterol Motil* 2016.
- Guyatt GH, Oxman AD, Vist GE, et al. GRADE: an emerging consensus on rating quality of evidence and strength of recommendations. *BMJ* 2008;336:924–6.
- Guyatt G, Oxman AD, Akl EA, et al. GRADE guidelines: 1. Introduction-GRADE evidence profiles and summary of findings tables. *J Clin Epidemiol* 2011;64:383–94.
- Guyatt GH, Oxman AD, Kunz R, et al. GRADE guidelines: 2. Framing the question and deciding on important outcomes. *J Clin Epidemiol* 2011;64:395–400.
- Balshem H, Helfand M, Schunemann HJ, et al. GRADE guidelines: 3. Rating the quality of evidence. *J Clin Epidemiol* 2011;64:401–6.
- Guyatt GH, Oxman AD, Vist G, et al. GRADE guidelines: 4. Rating the quality of evidence—study limitations (risk of bias). *J Clin Epidemiol* 2011;64:407–15.
- Hsu J, Broek JL, Terracciano L, et al. Application of GRADE: making evidence-based recommendations about diagnostic tests in clinical practice guidelines. *Implement Sci* 2011;6:62.
- Dudley HA, Sinclair IS, Mc LI, et al. Intestinal pseudo-obstruction. *J R Coll Surg Edinb* 1958;3:206–17.
- Byrne WJ, Cipel L, Euler AR, et al. Chronic idiopathic intestinal pseudo-obstruction syndrome in children—clinical characteristics and prognosis. *J Pediatr* 1977;90:585–9.
- Gibbons JC, Sullivan JF. Chronic idiopathic pseudo-obstructive bowel disease. *Am J Gastroenterol* 1978;70:306–13.
- De Giorgio R, Cogliandro RF, Barbara G, et al. Chronic intestinal pseudo-obstruction: clinical features, diagnosis, and therapy. *Gastroenterol Clin North Am* 2011;40:787–807.
- Masaki T, Sugihara K, Nakajima A, et al. Nationwide survey on adult type chronic intestinal pseudo-obstruction in surgical institutions in Japan. *Surg Today* 2012;42:264–71.
- Hanks JB, Meyers WC, Andersen DK, et al. Chronic primary intestinal pseudo-obstruction. *Surgery* 1981;89:175–82.
- Mann SD, Debinski HS, Kamm MA. Clinical characteristics of chronic idiopathic intestinal pseudo-obstruction in adults. *Gut* 1997;41:675–81.
- Pitt HA, Mann LL, Berquist WE, et al. Chronic intestinal pseudo-obstruction. Management with total parenteral nutrition and a venting enterostomy. *Arch Surg* 1985;120:614–8.
- Stanghellini V, Camilleri M, Malagelada JR. Chronic idiopathic intestinal pseudo-obstruction: clinical and intestinal manometric findings. *Gut* 1987;28:5–12.
- Stanghellini V, Cogliandro RF, De Giorgio R, et al. Natural history of chronic idiopathic intestinal pseudo-obstruction in adults: a single center study. *Clin Gastroenterol Hepatol* 2005;3:449–58.
- Vargas JH, Sachs P, Ament ME. Chronic intestinal pseudo-obstruction syndrome in pediatrics. Results of a national survey by members of the North American Society of Pediatric Gastroenterology and Nutrition. *J Pediatr Gastroenterol Nutr* 1988;7:323–32.
- Howard L, Ashley C. Management of complications in patients receiving home parenteral nutrition. *Gastroenterology* 2003;124:1651–61.
- Puri P, Shinkai M. Megacystis microcolon intestinal hypoperistalsis syndrome. *Semin Pediatr Surg* 2005;14:58–63.
- Schuffler MD, Pagon RA, Schwartz R, et al. Visceral myopathy of the gastrointestinal and genitourinary tracts in infants. *Gastroenterology* 1988;94:892–8.
- Martin JE, Benson M, Swash M, et al. Myofibroblasts in hollow visceral myopathy: the origin of gastrointestinal fibrosis? *Gut* 1993;34:999–1001.
- Jayachandar J, Frank JL, Jonas MM. Isolated intestinal myopathy resembling progressive systemic sclerosis in a child. *Gastroenterology* 1988;95:1114–8.
- Lowsky R, Davidson G, Wolman S, et al. Familial visceral myopathy associated with a mitochondrial myopathy. *Gut* 1993;34:279–83.
- Schuffler MD, Lowe MC, Bill AH. Studies of idiopathic intestinal pseudoobstruction. I. Hereditary hollow visceral myopathy: clinical and pathological studies. *Gastroenterology* 1977;73:327–38.
- Schuffler MD, Pope CE 2nd. Studies of idiopathic intestinal pseudoobstruction. II. Hereditary hollow visceral myopathy: family studies. *Gastroenterology* 1977;73:339–44.
- Jones SC, Dixon MF, Lintott DJ, et al. Familial visceral myopathy. A family with involvement of four generations. *Dig Dis Sci* 1992;37:464–9.
- Threlkeld AB, Miller NR, Golnik KC, et al. Ophthalmic involvement in myo-neuro-gastrointestinal encephalopathy syndrome. *Am J Ophthalmol* 1992;114:322–8.
- Li V, Hostein J, Romero NB, et al. Chronic intestinal pseudoobstruction with myopathy and ophthalmoplegia. A muscular biochemical study of a mitochondrial disorder. *Dig Dis Sci* 1992;37:456–63.
- Ahlfors F, Linander H, Lindstrom M, et al. Familial intestinal degenerative neuropathy associated with chronic intestinal pseudo-obstruction. *Neurogastroenterol Motil* 2011;23:347–55e159.
- Roper EC, Gibson A, McAlindon ME, et al. Familial visceral neuropathy: a defined entity? *Am J Med Genet A* 2005;137A:249–54.
- Niwamoto H, Okamoto E, Toyosaka A, et al. Sporadic visceral neuropathy. *Surg Today* 1995;25:763–70.
- Low PA. Autonomic neuropathies. *Curr Opin Neurol* 1994;7:402–6.
- Camilleri M, Balm RK, Low PA. Autonomic dysfunction in patients with chronic intestinal pseudo-obstruction. *Clin Auton Res* 1993;3:95–100.
- Lehtonen HJ, Sipponen T, Tojkander S, et al. Segregation of a missense variant in enteric smooth muscle actin gamma-2 with autosomal dominant familial visceral myopathy. *Gastroenterology* 2012;143:1482–91e3.
- Cho YH, Park JH, Park DY, et al. Segmental transposition of ileal muscle layers: a rare cause of myopathic pseudoobstruction in a newborn. *J Pediatr Surg* 2011;46:e1–3.
- Dewit S, de Hertogh G, Geboes K, et al. Chronic intestinal pseudo-obstruction caused by an intestinal inflammatory myopathy: case report and review of the literature. *Neurogastroenterol Motil* 2008;20:343–8.
- Kenny SE, Vanderwinden JM, Rintala RJ, et al. Delayed maturation of the interstitial cells of Cajal: a new diagnosis for transient neonatal pseudoobstruction. Report of two cases. *J Pediatr Surg* 1998;33:94–8.
- Yamataka A, Ohshiro K, Kobayashi H, et al. Abnormal distribution of intestinal pacemaker (C-KIT-positive) cells in an infant with chronic idiopathic intestinal pseudoobstruction. *J Pediatr Surg* 1998;33:859–62.
- Feldstein AE, Miller SM, El-Youssef M, et al. Chronic intestinal pseudoobstruction associated with altered interstitial cells of cajal networks. *J Pediatr Gastroenterol Nutr* 2003;36:492–7.
- Farrugia G. Interstitial cells of Cajal in health and disease. *Neurogastroenterol Motil* 2008;20(Suppl 1):54–63.
- Schappi MG, Smith VV, Milla PJ, et al. Eosinophilic myenteric ganglionitis is associated with functional intestinal obstruction. *Gut* 2003;52:752–5.
- Haas S, Bindl L, Fischer HP. Autoimmune enteric leiomyositis: a rare cause of chronic intestinal pseudo-obstruction with specific morphological features. *Hum Pathol* 2005;36:576–80.
- Ruuska TH, Karikoski R, Smith VV, et al. Acquired myopathic intestinal pseudo-obstruction may be due to autoimmune enteric leiomyositis. *Gastroenterology* 2002;122:1133–9.
- Garone C, Tadesse S, Hirano M. Clinical and genetic spectrum of mitochondrial neurogastrointestinal encephalomyopathy. *Brain* 2011;134:3326–32.

51. Perez-Atayde AR. Diagnosis of mitochondrial neurogastrointestinal encephalopathy disease in gastrointestinal biopsies. *Hum Pathol* 2013;44:1440–6.
52. Nishino I, Spinazzola A, Papadimitriou A, et al. Mitochondrial neurogastrointestinal encephalomyopathy: an autosomal recessive disorder due to thymidine phosphorylase mutations. *Ann Neurol* 2000;47:792–800.
53. Blondon H, Polivka M, Joly F, et al. Digestive smooth muscle mitochondrial myopathy in patients with mitochondrial-neuro-gastro-intestinal encephalomyopathy (MNGIE). *Gastroenterol Clin Biol* 2005;29:773–8.
54. Qualia CM, Brown MR, Ryan CK, et al. Oral Mucosal Neuromas Leading to the Diagnosis of Multiple Endocrine Neoplasia Type 2B in a Child With Intestinal Pseudo-obstruction. *Gastroenterol Hepatol (N Y)* 2007;3:208–11.
55. Erdogan MF, Gulec B, Gursay A, et al. Multiple endocrine neoplasia 2B presenting with pseudo-Hirschsprung's disease. *J Natl Med Assoc* 2006;98:783–6.
56. Grobmyer SR, Guillem JG, O'Riordain DS, et al. Colonic manifestations of multiple endocrine neoplasia type 2B: report of four cases. *Dis Colon Rectum* 1999;42:1216–9.
57. Ohkubo H, Iida H, Takahashi H, et al. An epidemiologic survey of chronic intestinal pseudo-obstruction and evaluation of the newly proposed diagnostic criteria. *Digestion* 2012;86:12–9.
58. Kleckner FS. Dermatomyositis and its manifestations in the gastrointestinal tract. *Am J Gastroenterol* 1970;53:141–6.
59. Laskin BL, Choyke P, Keenan GF, et al. Novel gastrointestinal tract manifestations in juvenile dermatomyositis. *J Pediatr* 1999;135:371–4.
60. Sjogren RW. Gastrointestinal features of scleroderma. *Curr Opin Rheumatol* 1996;8:569–75.
61. Perlemuter G, Cacoub P, Wechsler B, et al. [Chronic intestinal pseudo-obstruction secondary to connective tissue diseases]. *Gastroenterol Clin Biol* 2001;25:251–8.
62. Adachi Y, Yabana T, Kohri T, et al. [A case of chronic idiopathic intestinal pseudo-obstruction with Sjogren's syndrome]. *Nihon Shokakibyō Gakkai Zasshi* 1990;87:1223–7.
63. Khairullah S, Jasmin R, Yahya F, et al. Chronic intestinal pseudo-obstruction: a rare first manifestation of systemic lupus erythematosus. *Lupus* 2013;22:957–60.
64. Kansal A, Jain A, Thenozhi S, et al. Intestinal pseudo-obstruction associated with biliary tract dilatation in a patient with systemic lupus erythematosus. *Lupus* 2013;22:87–91.
65. Zhang J, Fang M, Wang Y, et al. Intestinal pseudo-obstruction syndrome in systemic lupus erythematosus. *Lupus* 2011;20:1324–8.
66. Yamazaki-Nakashimada MA, Rodriguez-Jurado R, Ortega-Salgado A, et al. Intestinal pseudoobstruction associated with eosinophilic enteritis as the initial presentation of systemic lupus erythematosus in children. *J Pediatr Gastroenterol Nutr* 2009;48:482–6.
67. Pelizzo G, Villanacci V, Salemm M, et al. Intestinal pseudo-obstruction due to small bowel alpha-actin deficiency in a child with Ehlers-Danlos syndrome. *Tech Coloproctol* 2013.
68. Sato T, Ito H, Miyazaki S, et al. Megacystis and megacolon in an infant with Ehlers-Danlos syndrome. *Acta Paediatr Jpn* 1993;35:358–60.
69. Camelo AL, Awad RA, Madrazo A, et al. Esophageal motility disorders in Mexican patients with Duchenne's muscular dystrophy. *Acta Gastroenterol Latinoam* 1997;27:119–22.
70. Bensen ES, Jaffe KM, Tarr PI. Acute gastric dilatation in Duchenne muscular dystrophy: a case report and review of the literature. *Arch Phys Med Rehabil* 1996;77:512–4.
71. Garcia Aroca J, Sanz N, Alonso JL, et al. [Intestinal pseudo-obstruction secondary to systemic neuropathies and myopathies]. *Cir Pediatr* 1994;7:115–20.
72. Leon SH, Schuffler MD, Kettler M, et al. Chronic intestinal pseudo-obstruction as a complication of Duchenne's muscular dystrophy. *Gastroenterology* 1986;90:455–9.
73. Kim YJ, Kim HS, Park SY, et al. Intestinal amyloidosis with intractable diarrhea and intestinal pseudo-obstruction. *Korean J Gastroenterol* 2012;60:172–6.
74. Liapis K, Michelis FV, Delimpasi S, et al. Intestinal pseudo-obstruction associated with amyloidosis. *Amyloid* 2011;18:76–8.
75. Illescas Megias V, Marquez Moreno AJ. [Intestinal pseudo-obstruction in Steinert myotonic dystrophy: a clinical-radiological description of 2 cases]. *Radiologia* 2013;55:88–90.
76. Bruinenberg JF, Rieu PN, Gabreels FM, et al. Intestinal pseudo-obstruction syndrome in a child with myotonic dystrophy. *Acta Paediatr* 1996;85:121–3.
77. Boller M, Ficocchi C, Brown CH. Pseudoobstruction in ceroidosis. *AJR Am J Roentgenol* 1976;127:277–9.
78. Michaely HJ, Daroca PJ, Plavsic BM. [Brown bowel syndrome—an unusual etiology of pseudo-obstruction of the small intestine]. *Rofo* 2003;175:1143–4.
79. Assor P, Negreanu L, Picon L, et al. Slowly regressing acute pancytopenia associated with esophageal achalasia: a case report. *Gastroenterol Clin Biol* 2008;32:46–50.
80. Palao S, Corral I, Vera R, et al. Progressive dysautonomia as initial manifestation of anti-Hu antibody-related syndrome. *Neurologia* 2007;22:899–902.
81. Besnard M, Faure C, Fromont-Hankard G, et al. Intestinal pseudo-obstruction and acute pancytopenia associated with Epstein-Barr virus infection. *Am J Gastroenterol* 2000;95:280–4.
82. Taguchi T, Ikeda K, Shono T, et al. Autonomic innervation of the intestine from a baby with megacystis microcolon intestinal hypoperistalsis syndrome: I. Immunohistochemical study. *J Pediatr Surg* 1989;24:1264–6.
83. Yamanaka Y, Sakakibara R, Asahina M, et al. Chronic intestinal pseudo-obstruction as the initial feature of pure autonomic failure. *J Neurol Neurosurg Psychiatry* 2006;77:800.
84. Sinha SK, Kochhar R, Rana S, et al. Intestinal pseudo-obstruction due to neurofibromatosis responding to cisapride. *Indian J Gastroenterol* 2000;19:83–4.
85. Hanemann CO, Hayward C, Hilton DA. Neurofibromatosis type 1 with involvement of the enteric nerves. *J Neurol Neurosurg Psychiatry* 2007;78:1163–4.
86. Aoki Y, Hosaka S, Kiyosawa K. Intestinal pseudo-obstruction in a diabetic man: role of the mitochondrial A3243G mutation. *Ann Intern Med* 2002;137:703–4.
87. Reid B, DiLorenzo C, Travis L, et al. Diabetic gastroparesis due to postprandial antral hypomotility in childhood. *Pediatrics* 1992;90:43–6.
88. Hendriks G, McPartland J, El-Matary W. Gastrointestinal presentation and outcome of perinatal cytomegalovirus infection. *BMJ Case Rep* 20132013.
89. Ategbro S, Turck D, Gottrand F, et al. Chronic intestinal pseudo-obstruction associated with cytomegalovirus infection in an infant. *J Pediatr Gastroenterol Nutr* 1996;23:457–60.
90. Precupanu CM, Girodet J, Mariani P, et al. Pseudo-bowel obstruction due to varicella zoster virus infection after autologous stem cell transplantation. *Am J Hematol* 2009;84:127–8.
91. Tanida E, Izumi M, Abe T, et al. Disseminated varicella-zoster virus infection complicated with severe abdominal pain and colonic pseudo-obstruction. *Nihon Shokakibyō Gakkai Zasshi* 2013;110:839–45.
92. De Giorgio R, Ricciardiello L, Naponelli V, et al. Chronic intestinal pseudo-obstruction related to viral infections. *Transplant Proc* 2010;42:9–14.
93. Selgrad M, De Giorgio R, Fini L, et al. JC virus infects the enteric glia of patients with chronic idiopathic intestinal pseudo-obstruction. *Gut* 2009;58:25–32.
94. Uc A, Vasiliauskas E, Piccoli DA, et al. Chronic intestinal pseudoobstruction associated with fetal alcohol syndrome. *Dig Dis Sci* 1997;42:1163–7.
95. Abboud B, Sayegh R, Medlej R, et al. A rare manifestation of hypothyroidism: intestinal obstruction. Report of 2 cases and review of the literature. *J Med Liban* 1999;47:364–6.
96. Bassotti G, Pagliacci MC, Nicoletti I, et al. Intestinal pseudoobstruction secondary to hypothyroidism. Importance of small bowel manometry. *J Clin Gastroenterol* 1992;14:56–8.
97. Siegrist D, Teuscher AU, Ruchti C. Intestinal paralysis in long-term diabetes mellitus. *Praxis (Bern 1994)* 1998;87:769–72.
98. Camilleri M, Parkman HP, Shafi MA, et al. Clinical guideline: management of gastroparesis. *Am J Gastroenterol* 2013;108:18–37quiz 8.
99. Wu HW, Liou WP, Chou CC, et al. Pheochromocytoma presented as intestinal pseudo-obstruction and hyperamylasemia. *Am J Emerg Med* 2008;26:971e1-4.

100. Geelhoed GW. Colonic pseudo-obstruction in surgical patients. *Am J Surg* 1985;149:258–65.
101. Lutz P, Maring D, Tschampa HJ, et al. A 25-year-old patient with colonic pseudo-obstruction, hyponatremia, hypertension, and diffuse pain. *Med Klin (Munich)* 2010;105:267–72.
102. Negrini S, Zoppoli G, Setti M, et al. Paralytic ileus and liver failure—an unusual presentation of advanced erythropoietic protoporphyria. *Dig Dis Sci* 2009;54:411–5.
103. Koberstein B, Eysselein VE, Balzer K, et al. Paralytic ileus as an initial manifestation of malignant VIPoma of the pancreas—case report with review of the literature. *Z Gastroenterol* 1990;28:295–301.
104. Sundar U, Lakkas Y, Asole D, et al. Gitelman's syndrome presenting as recurrent paralytic ileus due to chronic renal tubular K⁺ wasting. *J Assoc Physicians India* 2010;58:322–4.
105. Golzarian J, Scott HW Jr, Richards WO. Hypermagnesemia-induced paralytic ileus. *Dig Dis Sci* 1994;39:1138–42.
106. Singh G, Hershman MJ, Loft DE, et al. Partial malrotation associated with pseudo-obstruction of the small bowel. *Br J Clin Pract* 1993;47:274–5.
107. Devane SP, Coombes R, Smith VV, et al. Persistent gastrointestinal symptoms after correction of malrotation. *Arch Dis Child* 1992;67:218–21.
108. Bagwell CE, Filler RM, Cutz E, et al. Neonatal intestinal pseudo-obstruction. *J Pediatr Surg* 1984;19:732–9.
109. Vanderwinden JM, Dassonville M, Van der Veken E, et al. Post-necrotising enterocolitis pseudo-obstruction treated with Cisapride. *Z Kinderchir* 1990;45:282–5.
110. Matta R, Aramouni E, Mouawad P, et al. Celiac disease presenting as acute colonic pseudo-obstruction. *J Med Liban* 2012;60:110–2.
111. Cluysenaer OJ, van Tongeren JH. Pseudo-obstruction in coeliac sprue. *Neth J Med* 1987;31:300–4.
112. Cluysenaer OJ, van Tongeren JH. Coeliac disease presenting with intestinal pseudo-obstruction. *Gut* 1985;26:538.
113. Ooms AH, Verheij J, Hulst JM, et al. Eosinophilic myenteric ganglionitis as a cause of chronic intestinal pseudo-obstruction. *Virchows Arch* 2012;460:123–7.
114. Losanoff JE, Kjossev KT, Katrov ET. Eosinophilic enterocolitis and visceral neuropathy with chronic intestinal pseudo-obstruction. *J Clin Gastroenterol* 1999;28:368–71.
115. Myrholm T, Ladefoged K, Jarnum S. Chronic intestinal pseudo-obstruction in patients with extensive bowel resection for Crohn's disease. *Scand J Gastroenterol* 1988;23:380–4.
116. Carethers JM, McDonnell WM, Owyang C, et al. Massive secretory diarrhea and pseudo-obstruction as the initial presentation of Crohn's disease. *J Clin Gastroenterol* 1996;23:55–9.
117. Rolachon A, Bost R, Bichard P, et al. Radiotherapy: a rare etiology of chronic intestinal pseudo-obstruction. *Gastroenterol Clin Biol* 1993;17:229–30.
118. Husebye E, Hauer-Jensen M, Kjørstad K, et al. Severe late radiation enteropathy is characterized by impaired motility of proximal small intestine. *Dig Dis Sci* 1994;39:2341–9.
119. Meneghelli UG. Chagasic enteropathy. *Rev Soc Bras Med Trop* 2004;37:252–60.
120. Tiao MM, Huang LT, Liang CD, et al. Atypical Kawasaki disease presenting as intestinal pseudo-obstruction. *J Formos Med Assoc* 2006;105:252–5.
121. Eck SL, Morse JH, Janssen DA, et al. Angioedema presenting as chronic gastrointestinal symptoms. *Am J Gastroenterol* 1993;88:436–9.
122. Shemer SA, Marley L, Miller F. Intestinal pseudo-obstruction due to mitochondrial cytopathy. *ANZ J Surg* 2010;80:571.
123. Bianchi A, Ubach M. Acute colonic pseudo-obstruction caused by opiates treated with naloxone. *Med Clin (Barc)* 1994;103:78.
124. Kapur RP. Neuropathology of paediatric chronic intestinal pseudo-obstruction and related animal models. *J Pathol* 2001;194:277–88.
125. Muller-Lissner SA. Adverse effects of laxatives: fact and fiction. *Pharmacology* 1993;47(Suppl 1):138–45.
126. Schultz HS, Vernon B. Intestinal pseudo-obstruction related to using verapamil. *West J Med* 1989;151:556–8.
127. Lemye M, Chaaban R, Collet F. Psychotic woman with painful abdominal distension. Life-threatening psychotropic drug-induced gastrointestinal hypomotility. *Ann Emerg Med* 2009;54:756–9.
128. McMahon AJ. Amitriptyline overdose complicated by intestinal pseudo-obstruction and caecal perforation. *Postgrad Med J* 1989;65:948–9.
129. Esquerdo Galiana G, Briceno Garcia H, Llorca Ferrandiz C, et al. Paralytic ileus due to vinorelbine. *Clin Transl Oncol* 2005;7:169–70.
130. Saito H, Yamamoto T, Kimura M, et al. Prostaglandin F₂ alpha in the treatment of vinca alkaloid-induced ileus. *Am J Med* 1993;95:549–51.
131. Mifune D, Tsukada H, Hosoi M, et al. Chronic intestinal pseudo-obstruction as a paraneoplastic presentation of limited-stage small cell lung cancer. *Nihon Kokyuki Gakkai Zasshi* 2010;48:439–43.
132. Wildhaber B, Niggli F, Stallmach T, et al. Intestinal pseudo-obstruction as a paraneoplastic syndrome in ganglioneuroblastoma. *Eur J Pediatr Surg* 2002;12:429–31.
133. Simonelli M, Banna GL, Santoro A. Thymoma associated with myasthenia and autonomic anti-Hu paraneoplastic neuropathy. *Tumori* 2009;95:243–7.
134. Rex DK. Acute colonic pseudo-obstruction (Ogilvie's syndrome). *Gastroenterologist* 1994;2:233–8.
135. Yilmazlar A, Iscimen R, Bilgen OF, et al. Ogilvie's syndrome following bilateral knee arthroplasty: a case report. *Acta Orthop Traumatol Turc* 2012;46:220–2.
136. Hou JW, Wang TR. Amelia, dextrocardia, asplenia, and congenital short bowel in deleted ring chromosome 4. *J Med Genet* 1996;33:879–81.
137. Di Lorenzo C. Pseudo-obstruction: current approaches. *Gastroenterology* 1999;116:980–7.
138. Amiot A, Joly F, Alves A, et al. Long-term outcome of chronic intestinal pseudo-obstruction adult patients requiring home parenteral nutrition. *Am J Gastroenterol* 2009;104:1262–70.
139. Lindberg G, Iwarzon M, Tornblom H. Clinical features and long-term survival in chronic intestinal pseudo-obstruction and enteric dysmotility. *Scand J Gastroenterol* 2009;44:692–9.
140. Iida H, Ohkubo H, Inamori M, et al. Epidemiology and clinical experience of chronic intestinal pseudo-obstruction in Japan: a nationwide epidemiologic survey. *J Epidemiol* 2013;23:288–94.
141. Muto M, Sato R, Fujiya M, et al. Pseudo-diverticular formation due to a cytomegalovirus infection in the colorectum. *Dig Endosc* 2012;24:193.
142. Granata C, Puri P. Megacystis-microcolon-intestinal hypoperistalsis syndrome. *J Pediatr Gastroenterol Nutr* 1997;25:12–9.
143. Chapman AH, McNamara M, Porter G. The acute contrast enema in suspected large bowel obstruction: value and technique. *Clin Radiol* 1992;46:273–8.
144. Di Lorenzo C. Surgery in intestinal pseudo-obstruction: pro. *J Pediatr Gastroenterol Nutr* 2005;41(Suppl 1):S64–5.
145. Zakharov NL, Bairov GA. The treatment of newborns with gastrochisis. *Vestn Khir Im I I Grek* 1992;149:346–50.
146. Faure C. Chronic intestinal pseudo-obstruction syndrome. In: Walker W, Goulet O, Kleinman R, eds. *Pediatric Gastrointestinal Disease*. Ontario: BC Decker; 2004:1044–54.
147. de Betue CT, Boersma D, Oomen MW, et al. Volvulus as a complication of chronic intestinal pseudo-obstruction syndrome. *Eur J Pediatr* 2011;170:1591–5.
148. Osuka A, Ikegami R, Watanabe Y. Splenic flexure volvulus in a child with chronic idiopathic intestinal pseudo-obstruction syndrome. *Pediatr Surg Int* 2006;22:833–5.
149. Zubarovskii IN, Plutakhin KA. The Ogilvie syndrome after restorative surgery on the large intestine. *Vestn Khir Im I I Grek* 2009;168:71–2.
150. Boige N, Faure C, Cargill G, et al. Manometrical evaluation in visceral neuropathies in children. *J Pediatr Gastroenterol Nutr* 1994;19:71–7.
151. Heitlinger LA, McClung HJ, Murray RD, et al. Recurrent pancreatitis in three patients with chronic idiopathic intestinal pseudo-obstruction. *J Pediatr Gastroenterol Nutr* 1991;13:92–5.
152. Shimotake T, Iwai N, Yanagihara J, et al. Biliary tract complications in patients with hypoganglionosis and chronic idiopathic intestinal pseudo-obstruction syndrome. *J Pediatr Surg* 1993;28:189–92.
153. Higman D, Peters P, Stewart M. Familial hollow visceral myopathy with varying urological manifestations. *Br J Urol* 1992;70:435–8.
154. Ghavamian R, Wilcox DT, Duffy PG, et al. The urological manifestations of hollow visceral myopathy in children. *J Urol* 1997;158 (3 Pt 2):1286–90.

155. Lapointe SP, Rivet C, Goulet O, et al. Urological manifestations associated with chronic intestinal pseudo-obstructions in children. *J Urol* 2002;168 (4 Pt 2):1768–70.
156. Auricchio A, Brancolini V, Casari G, et al. The locus for a novel syndromic form of neuronal intestinal pseudoobstruction maps to Xq28. *Am J Hum Genet* 1996;58:743–8.
157. Gargiulo A, Auricchio R, Barone MV, et al. Filamin A is mutated in X-linked chronic idiopathic intestinal pseudo-obstruction with central nervous system involvement. *Am J Hum Genet* 2007;80:751–8.
158. Vignon H. Disorders of transit in acute pancreatitis and peritonitis. *Ann Anesthesiol Fr* 1974;15 (SPEC NO 1):85–7.
159. Wimmer RD, Skibba RM. Pseudo-obstruction of colon: resolution following paracentesis. *J Kans Med Soc* 1976;77:387–8.
160. Sule AZ, Uba AF, Kidmas AT. Acute colonic pseudo-obstruction (Ogilvie's syndrome). A case presentation and review of literature. *Niger J Med* 2002;11:56–9.
161. Scolapio JS, Savoy AD, Kaplan J, et al. Sleep patterns of cyclic parenteral nutrition, a pilot study: are there sleepless nights? *JPEN J Parenter Enteral Nutr* 2002;26:214–7.
162. Pingault V, Guiochon-Mantel A, Bondurand N, et al. Peripheral neuropathy with hypomyelination, chronic intestinal pseudo-obstruction and deafness: a developmental "neural crest syndrome" related to a SOX10 mutation. *Ann Neurol* 2000;48:671–6.
163. Pingault V, Girard M, Bondurand N, et al. SOX10 mutations in chronic intestinal pseudo-obstruction suggest a complex physiopathological mechanism. *Hum Genet* 2002;111:198–206.
164. Ortiz-Alvarez O, Cabral D, Prendiville JS, et al. Intestinal pseudo-obstruction as an initial presentation of systemic sclerosis in two children. *Br J Rheumatol* 1997;36:280–4.
165. Gohil A, Croffie JM, Fitzgerald JF, et al. Reversible intestinal pseudo-obstruction associated with neural crest tumors. *J Pediatr Gastroenterol Nutr* 2001;33:86–8.
166. Yakan S, Caliskan C, Kaplan H, et al. Superior mesenteric artery syndrome: a rare cause of intestinal obstruction. Diagnosis and surgical management. *Indian J Surg* 2013;75:106–10.
167. Ariza A, Coll J, Fernandez-Figueras MT, et al. Desmin myopathy: a multisystem disorder involving skeletal, cardiac, and smooth muscle. *Hum Pathol* 1995;26:1032–7.
168. Zawaideh MA, Duncan B, Joseph MW, et al. Treatment of chronic hypertension with intravenous enalaprilat and transdermal clonidine. *Pediatr Nephrol* 2001;16:85–6.
169. Merlin A, Soyer P, Boudiaf M, et al. Chronic intestinal pseudo-obstruction in adult patients: multidetector row helical CT features. *Eur Radiol* 2008;18:1587–95.
170. Hase T, Kodama M, Kishida A, et al. The application of radio-opaque markers prior to ileostomy in an infant with chronic intestinal pseudo-obstruction: report of a case. *Surg Today* 1998;28:83–6.
171. Rudolph CD, Hyman PE, Altschuler SM, et al. Diagnosis and treatment of chronic intestinal pseudo-obstruction in children: report of consensus workshop. *J Pediatr Gastroenterol Nutr* 1997;24:102–12.
172. Di Lorenzo C, Youssef NN. Diagnosis and management of intestinal motility disorders. *Semin Pediatr Surg* 2010;19:50–8.
173. Vasile I, Vilcea D, Mogos D, et al. Functional secondary megaduodenum. *Chirurgia (Bucur)* 2003;98:553–60.
174. Vilcea D, Vasile I. Chronic intestinal pseudoobstruction syndrome in adults. *Chirurgia (Bucur)* 2004;99:117–24.
175. Green AD, Belkind-Gerson J, Surjanhata BC, et al. Wireless motility capsule test in children with upper gastrointestinal symptoms. *J Pediatr* 2013;162:1181–7.
176. Ohkubo H, Kessoku T, Fuyuki A, et al. Assessment of small bowel motility in patients with chronic intestinal pseudo-obstruction using cine-MRI. *Am J Gastroenterol* 2013;108:1130–9.
177. Cardosi RJ, Nackley AC, Londono J, et al. Embolization for advanced abdominal pregnancy with a retained placenta. A case report. *J Reprod Med* 2002;47:861–3.
178. Cucchiara S, Borrelli O, Salvia G, et al. A normal gastrointestinal motility excludes chronic intestinal pseudoobstruction in children. *Dig Dis Sci* 2000;45:258–64.
179. Hyman PE, Bursch B, Beck D, et al. Discriminating pediatric condition falsification from chronic intestinal pseudo-obstruction in toddlers. *Child Maltreat* 2002;7:132–7.
180. Hyman PE, McDiarmid SV, Napolitano J, et al. Antroduodenal motility in children with chronic intestinal pseudo-obstruction. *J Pediatr* 1988;112:899–905.
181. Connor FL, Di Lorenzo C. Chronic intestinal pseudo-obstruction: assessment and management. *Gastroenterology* 2006;130(2 Suppl 1):S29–36.
182. Camilleri M. Jejunal manometry in distal subacute mechanical obstruction: significance of prolonged simultaneous contractions. *Gut* 1989;30:468–75.
183. Askerkhanov RP, Abdullaev MR. Pathogenesis and treatment of post-operative intestinal paresis. *Klin Khir* 1983;27–9.
184. Di Lorenzo C, Flores AF, Buie T, et al. Intestinal motility and jejunal feeding in children with chronic intestinal pseudo-obstruction. *Gastroenterology* 1995;108:1379–85.
185. Hyman PE, Di Lorenzo C, McAdams L, et al. Predicting the clinical response to cisapride in children with chronic intestinal pseudo-obstruction. *Am J Gastroenterol* 1993;88:832–6.
186. Fell JM, Smith VV, Milla PJ. Infantile chronic idiopathic intestinal pseudo-obstruction: the role of small intestinal manometry as a diagnostic tool and prognostic indicator. *Gut* 1996;39:306–11.
187. Di Lorenzo C, Flores AF, Reddy SN, et al. Colonic manometry in children with chronic intestinal pseudo-obstruction. *Gut* 1993;34:803–7.
188. Weber O, Burger C, Fremerey R, et al. Acute colonic pseudoobstruction following fixation of a petrochanteric fracture. *Unfallchirurg* 2006;109:417–21.
189. Sigurdsson L, Reyes J, Kocoshis SA, et al. Intestinal transplantation in children with chronic intestinal pseudo-obstruction. *Gut* 1999;45:570–4.
190. Greig JD, Miles WF, Nixon SJ. Laparoscopic technique for small bowel biopsy. *Br J Surg* 1995;82:363.
191. Knowles CH, Silk DB, Darzi A, et al. Deranged smooth muscle alpha-actin as a biomarker of intestinal pseudo-obstruction: a controlled multinational case series. *Gut* 2004;53:1583–9.
192. Knowles CH, Veress B, Tornblom H, et al. Safety and diagnostic yield of laparoscopically assisted full-thickness bowel biopsy. *Neurogastroenterol Motil* 2008;20:774–9.
193. Lindberg G, Tornblom H, Iwarzon M, et al. Full-thickness biopsy findings in chronic intestinal pseudo-obstruction and enteric dysmotility. *Gut* 2009;58:1084–90.
194. King SK, Sutcliffe JR, Hutson JM. Laparoscopic seromuscular colonic biopsies: a surgeon's experience. *J Pediatr Surg* 2005;40:381–4.
195. Mazziotti MV, Langer JC. Laparoscopic full-thickness intestinal biopsies in children. *J Pediatr Gastroenterol Nutr* 2001;33:54–7.
196. Knowles CH, De Giorgio R, Kapur RP, et al. Gastrointestinal neuromuscular pathology: guidelines for histological techniques and reporting on behalf of the Gastro 2009 International Working Group. *Acta Neuropathol* 2009;118:271–301.
197. Martin JE, Hester TW, Aslam H, et al. Discordant practice and limited histopathological assessment in gastrointestinal neuromuscular disease. *Gut* 2009;58:1703–5.
198. Knowles CH, De Giorgio R, Kapur RP, et al. The London Classification of gastrointestinal neuromuscular pathology: report on behalf of the Gastro 2009 International Working Group. *Gut* 2010;59:882–7.
199. Mallick S, Prasenjit D, Prateek K, et al. Chronic intestinal pseudo-obstruction: systematic histopathological approach can clinch vital clues. *Virchows Arch* 2014;464:529–37.
200. Galmiche L, Jaubert F, Sauvat F, et al. Normal oxidative phosphorylation in intestinal smooth muscle of childhood chronic intestinal pseudo-obstruction. *Neurogastroenterol Motil* 2011;23:24–9e1.
201. Rudin C, Jenny P, Ohnacker H, et al. Absence of the enteric nervous system in the newborn: presentation of three patients and review of the literature. *J Pediatr Surg* 1986;21:313–8.
202. Giordano C, Sebastiani M, De Giorgio R, et al. Gastrointestinal dysmotility in mitochondrial neurogastrointestinal encephalomyopathy is caused by mitochondrial DNA depletion. *Am J Pathol* 2008;173:1120–8.
203. Kapur RP, Robertson SP, Hannibal MC, et al. Diffuse abnormal layering of small intestinal smooth muscle is present in patients with FLNA mutations and x-linked intestinal pseudo-obstruction. *Am J Surg Pathol* 2010;34:1528–43.

204. De Giorgio R, Sarnelli G, Corinaldesi R, et al. Advances in our understanding of the pathology of chronic intestinal pseudo-obstruction. *Gut* 2004;53:1549–52.
205. Smith VV, Milla PJ. Histological phenotypes of enteric smooth muscle disease causing functional intestinal obstruction in childhood. *Histopathology* 1997;31:112–22.
206. Alstead EM, Murphy MN, Flanagan AM, et al. Familial autonomic visceral myopathy with degeneration of muscularis mucosae. *J Clin Pathol* 1988;41:424–9.
207. Kapur RP, Fligner C, Maghsoodi B, et al. Gastrointestinal neuromuscular pathology in alpers disease. *Am J Surg Pathol* 2011;35:714–22.
208. Nguyen AT, Zacharin MR, Smith M, et al. Isolated intestinal ganglioneuromatosis with a new mutation of RET proto-oncogene. *Eur J Gastroenterol Hepatol* 2006;18:803–5.
209. Lyford G, Foxx-Orenstein A. Chronic intestinal pseudoobstruction. *Curr Treat Options Gastroenterol* 2004;7:317–25.
210. De Giorgio R, Guerrini S, Barbara G, et al. Inflammatory neuropathies of the enteric nervous system. *Gastroenterology* 2004;126:1872–83.
211. Bott L, Boute O, Mention K, et al. Congenital idiopathic intestinal pseudo-obstruction and hydrocephalus with stenosis of the aqueduct of Sylvius. *Am J Med Genet A* 2004;130A:84–7.
212. Nishino I, Spinazzola A, Hirano M. Thymidine phosphorylase gene mutations in MNGIE, a human mitochondrial disorder. *Science* 1999;283:689–92.
213. Giordano C, Powell H, Leopizzi M, et al. Fatal congenital myopathy and gastrointestinal pseudo-obstruction due to POLG1 mutations. *Neurology* 2009;72:1103–5.
214. Bonora E, Bianco F, Corceddu L, et al. Mutations in RAD21 disrupt regulation of APOB in patients with chronic intestinal pseudo-obstruction. *Gastroenterology* 2015;148:771–82e11.
215. Chetaille P, Preuss C, Burkhard S, et al. Mutations in SGOL1 cause a novel cohesinopathy affecting heart and gut rhythm. *Nat Genet* 2015;46:1245–9.
216. Bardosi A, Creutzfeldt W, DiMauro S, et al. Myo-, neuro-, gastrointestinal encephalopathy (MNGIE syndrome) due to partial deficiency of cytochrome-c-oxidase. A new mitochondrial multisystem disorder. *Acta Neuropathol* 1987;74:248–58.
217. Teitelbaum JE, Berde CB, Nurko S, et al. Diagnosis and management of MNGIE syndrome in children: case report and review of the literature. *J Pediatr Gastroenterol Nutr* 2002;35:377–83.
218. Spinazzola A, Marti R, Nishino I, et al. Altered thymidine metabolism due to defects of thymidine phosphorylase. *J Biol Chem* 2002;277:4128–33.
219. Lara MC, Valentino ML, Torres-Torronteras J, et al. Mitochondrial neurogastrointestinal encephalomyopathy (MNGIE): biochemical features and therapeutic approaches. *Biosci Rep* 2007;27:151–63.
220. Van Goethem G, Schwartz M, Lofgren A, et al. Novel POLG mutations in progressive external ophthalmoplegia mimicking mitochondrial neurogastrointestinal encephalomyopathy. *Eur J Hum Genet* 2003;11:547–9.
221. Mattsson T, Roos R, Sundkvist G, et al. Sympathetic nerve dysfunction is common in patients with chronic intestinal pseudo-obstruction. *J Clin Gastroenterol* 2008;42:174–7.
222. Sundkvist G, Almér L, Lilja B. Respiratory influence on heart rate in diabetes mellitus. *Br Med J* 1979;1:924–5.
223. Sundkvist G, Lilja B, Almér LO. Abnormal diastolic blood pressure and heart rate reactions to tilting in diabetes mellitus. *Diabetologia* 1980;19:433–8.
224. Bergström B, Manhem P, Brannert M, et al. Impaired responses of plasmacatecholamines to exercise in diabetic patients with abnormal heart rate reactions to tilt. *Clin Physiol* 1989;9:259–67.
225. Bornmyr S, Svensson H, Söderström T, et al. Finger skin blood flow in response to indirect cooling in normal subjects and in patients before and after sympathectomy. *Clin Physiol* 1998;18:103–7.
226. Freccero C, Svensson H, Bornmyr S, et al. Sympathetic and parasympathetic neuropathy are frequent in both type 1 and type 2 diabetic patients. *Diabetes Care* 2004;27:2936–41.
227. Parry-Jones A, Paine P, Ramdass R, et al. Unexplained gastrointestinal dysmotility: the clue may lie in the brain. *Gut* 2011;60:758.
228. Ito T, Sakakibara R, Sakakibara Y, et al. Medulla and gut. *Intern Med* 2004;43:1091.
229. Scarpelli M, Ricciardi GK, Beltramello A, et al. The role of brain MRI in mitochondrial neurogastrointestinal encephalomyopathy. *Neuroradiol J* 2013;26:520–30.
230. Kanesaka T, Sakakibara R, Ito S, et al. Intestinal pseudo-obstruction in acute myelitis. *Intern Med* 2006;45:35–6.
231. Koike H, Sobue G. Paraneoplastic neuropathy. *Handb Clin Neurol* 2013;115:713–26.
232. Sekiguchi Y, Takahashi H, Mori M, et al. Potassium channel antibody-associated encephalitis with hypothalamic lesions and intestinal pseudo-obstruction. *J Neurol Sci* 2008;269:176–9.
233. Man BL, Fu YP. Intestinal pseudo-obstruction as a presenting symptom of Guillain-Barré syndrome. *BMJ Case Rep* 2014.
234. Schwankovsky L, Mousa H, Rowhani A, et al. Quality of life outcomes in congenital chronic intestinal pseudo-obstruction. *Dig Dis Sci* 2002;47:1965–8.
235. Hyman P, Thapar N. Gastrointestinal motility and functional disorders in children. In: Faure, Lorenzo D, Thapar, eds. *Pediatric Neurogastroenterology: Pleae chec autor names and provid the publication loction in ref 236, 275.y*. Springer Inc; 2013:257–70.
236. Hyman P. Chronic intestinal pseudo-obstruction. In: Wyllie R, Hyams J, Kay M, eds. *Pediatric Gastrointestinal and Liver Disease*. Philadelphia: Elsevier; 2011:505–11.
237. Gariepy CE, Mousa H. Clinical management of motility disorders in children. *Semin Pediatr Surg* 2009;18:224–38.
238. D'Antiga L, Goulet O. Intestinal failure in children: the European view. *J Pediatr Gastroenterol Nutr* 2013;56:118–26.
239. Stanley JD, Bartlett JG, Dart BW, et al. Clostridium difficile infection. *Curr Probl Surg* 2013;50:302–37.
240. Lecomte T, Cavicchi M, Delchier JC. Small bowel pseudo-obstruction revealing an early scleroderma. Long-term efficacy of octreotide and erythromycin. *Gastroenterol Clin Biol* 2000;24:361–3.
241. Ionasescu V. Oculogastrointestinal muscular dystrophy. *Am J Med Genet* 1983;15:103–12.
242. Ortega Duarte A, Martin-Sanchez FJ, Gonzalez-Castillo J, et al. Lupinus mutabilis (chocho) water intoxication. *Med Clin (Bare)* 2013;140:43–4.
243. Morii K, Koyama Y, Shimizu Y. A 85-year-old man complaining of lumbago and back pain after recovery from pneumonia and paralytic ileus. *J Cardiol* 2003;42:285–8.
244. Lescut D, Colombel JF, Parent M, et al. An enigmatic occlusive syndrome. *Ann Gastroenterol Hepatol (Paris)* 1988;24:115–6.
245. Guarino N, Shima H, Puri P. Structural immaturity of the pylorus muscle in infantile hypertrophic pyloric stenosis. *Pediatr Surg Int* 2000;16:282–4.
246. Papadatou B, Ferretti F, Gambarara M, et al. Clinical heterogeneity of chronic intestinal pseudo-obstruction. *Transplant Proc* 1997;29:1872–3.
247. Pironi L, Goulet O, Buchman A, et al. Outcome on home parenteral nutrition for benign intestinal failure: a review of the literature and benchmarking with the European prospective survey of ESPEN. *Clin Nutr* 2012;31:831–45.
248. Di Lorenzo C, Lucanto C, Flores AF, et al. Effect of sequential erythromycin and octreotide on antroduodenal manometry. *J Pediatr Gastroenterol Nutr* 1999;29:293–6.
249. Longo WE, Vernava AM 3rd. Prokinetic agents for lower gastrointestinal motility disorders. *Dis Colon Rectum* 1993;36:696–708.
250. Chini P, Toskes PP, Waseem S, et al. Effect of azithromycin on small bowel motility in patients with gastrointestinal dysmotility. *Scand J Gastroenterol* 2012;47:422–7.
251. Sorhaug S, Steinshamn SL, Waldum HL. Octreotide treatment for paraneoplastic intestinal pseudo-obstruction complicating SCLC. *Lung Cancer* 2005;48:137–40.
252. Lee JW, Bang KW, Jang PS, et al. Neostigmine for the treatment of acute colonic pseudo-obstruction (ACPO) in pediatric hematologic malignancies. *Korean J Hematol* 2010;45:62–5.
253. Lipton AB, Knauer CM. Pseudo-obstruction of the bowel. Therapeutic trial of metoclopramide. *Am J Dig Dis* 1977;22:263–5.
254. Mazloun BW, Barnes JB, Lee M. Cisapride as a successful treatment for acute intestinal pseudo-obstruction. *South Med J* 1996;89:828–30.
255. Camilleri M, Malagelada JR, Abell TL, et al. Effect of six weeks of treatment with cisapride in gastroparesis and intestinal pseudoobstruction. *Gastroenterology* 1989;96:704–12.

256. Di Lorenzo C, Reddy SN, Villanueva-Meyer J, et al. Cisapride in children with chronic intestinal pseudoobstruction. An acute, double-blind, crossover, placebo-controlled trial. *Gastroenterology* 1991;101:1564–70.
257. Shim LS, Eslick GD, Kan AE, et al. A case of chronic intestinal pseudo-obstruction secondary to primary visceral myopathy. *Nat Clin Pract Gastroenterol Hepatol* 2008;5:584–8.
258. Hashizume N, Yagi M, Ushijima K, et al. Pharmacotherapy in patients with pediatric CIPO—a nationwide survey in Japan. *Pediatr Int* 2017;59:467–72.
259. Emmanuel AV, Shand AG, Kamm MA. Erythromycin for the treatment of chronic intestinal pseudo-obstruction: description of six cases with a positive response. *Aliment Pharmacol Ther* 2004;19:687–94.
260. Minami T, Nishibayashi H, Shinomura Y, et al. Effects of erythromycin in chronic idiopathic intestinal pseudo-obstruction. *J Gastroenterol* 1996;31:855–9.
261. Dranove J, Horn D, Reddy SN, et al. Effect of intravenous erythromycin on the colonic motility of children and young adults during colonic manometry. *J Pediatr Surg* 2010;45:777–83.
262. Emmanuel AV, Kamm MA, Roy AJ, et al. Randomised clinical trial: the efficacy of prucalopride in patients with chronic intestinal pseudo-obstruction—a double-blind, placebo-controlled, cross-over, multiple n = 1 study. *Aliment Pharmacol Ther* 2012;35:48–55.
263. McNamara R, Mihalakis MJ. Acute colonic pseudo-obstruction: rapid correction with neostigmine in the emergency department. *J Emerg Med* 2008;35:167–70.
264. O’Dea CJ, Brookes JH, Wattoo DA. The efficacy of treatment of patients with severe constipation or recurrent pseudo-obstruction with pyridostigmine. *Colorectal Dis* 2010;12:540–8.
265. Di Lorenzo C, Lucanto C, Flores AF, et al. Effect of octreotide on gastrointestinal motility in children with functional gastrointestinal symptoms. *J Pediatr Gastroenterol Nutr* 1998;27:508–12.
266. Ambartsumyan L, Flores A, Nurko S, et al. Utility of octreotide in advancing enteral feeds in children with chronic intestinal pseudo-obstruction. *Paediatr Drugs* 2016;18:387–92.
267. Song J, Yin J, Xu X, et al. Prokinetic effects of large-dose lubiprostone on gastrointestinal transit in dogs and its mechanisms. *AM J Transl Res* 2015;7:513–21.
268. Prapaitrakool S, Hollmann MW, Wartenberg HC, et al. Use of buprenorphine in children with chronic pseudoobstruction syndrome: case series and review of literature. *Clin J Pain* 2012;28:722–5.
269. Check JH, Cohen R. Successful treatment of a female with chronic pseudo-intestinal obstruction with sympathomimetic amines and thyroid hormone replacement. *Clin Exp Obstet Gynecol* 2010;37:115–6.
270. Nakae Y, Kishida H, Hakii Y, et al. [Distigmine bromide improves chronic intestinal pseudo-obstruction in a case of MELAS]. *Rinsho Shinkeigaku* 2007;47:177–9.
271. Hirakawa H, Ueno S, Matuda H, et al. Effect of the herbal medicine dai-kenchu-to on gastrointestinal motility in patients with megacystis-microcolon-intestinal hypoperistalsis syndrome (MMIHS) and chronic idiopathic intestinal pseudo-obstruction (CIIP): report of two cases. *Tokai J Exp Clin Med* 2009;34:28–33.
272. Gu L, Ding C, Tian H, et al. Serial frozen fecal microbiota transplantation in the treatment of chronic intestinal pseudo-obstruction: a preliminary study. *J Neurogastroenterol Motil* 2017;23:289–97.
273. Faure C. Chronic intestinal pseudo-obstruction syndrome. In: Walker W, Goulet O, Kleinman R, eds. *Pediatric Gastrointestinal Disease*. Ontario: BC Decker; 2004:1044–54.
274. Hyman P, Thapar N. Chronic intestinal pseudo-obstruction. In: Faure C, Di Lorenzo C, Thapar N, eds. *Pediatric Neurogastroenterology: Gastrointestinal Motility and Functional Disorders in Children*. Springer Inc; 2013:257–70.
275. Fonkalsrud EW, Pitt HA, Berquist WE, et al. Surgical management of chronic intestinal pseudo-obstruction in infancy and childhood. *Prog Pediatr Surg* 1989;24:221–5.
276. Pakarinen MP, Kurvinen A, Koivusalo AI, et al. Surgical treatment and outcomes of severe pediatric intestinal motility disorders requiring parenteral nutrition. *J Pediatr Surg* 2013;48:333–8.
277. Goulet O, Sauvat F, Jan D. Surgery for pediatric patients with chronic intestinal pseudo-obstruction syndrome. *J Pediatr Gastroenterol Nutr* 2005;41(Suppl 1):S66–8.
278. Irtan S, Bellaiche M, Brasher C, et al. Stomal prolapse in children with chronic intestinal pseudoobstruction: a frequent complication? *J Pediatr Surg* 2010;45:2234–7.
279. Lapointe R. Chronic idiopathic intestinal pseudo-obstruction treated by near total small bowel resection: a 20-year experience. *J Gastrointest Surg* 2010;14:1937–42.
280. Pakarinen MP, Koivusalo AI, Rintala RJ. Outcomes of intestinal failure—a comparison between children with short bowel and dysmotile intestine. *J Pediatr Surg* 2009;44:2139–44.
281. Goulet O, Jobert-Giraud A, Michel JL, et al. Chronic intestinal pseudo-obstruction syndrome in pediatric patients. *Eur J Pediatr Surg* 1999;9:83–9.
282. Nakajima T, Matsuhashi N, Nara S, et al. An adult case of midgut volvulus in familial visceral myopathy. *Pathol Int* 2012;62:554–8.
283. Altaf MA, Werlin SL, Sato TT, et al. Colonic volvulus in children with intestinal motility disorders. *J Pediatr Gastroenterol Nutr* 2009;49:59–62.
284. Tatterton M, El-Khatib C. Caecal volvulus in a patient with chronic intestinal pseudo-obstruction. *Ann R Coll Surg Engl* 2011;93:e131–2.
285. Teich S, Mousa HM, Punati J, et al. Efficacy of permanent gastric electrical stimulation for the treatment of gastroparesis and functional dyspepsia in children and adolescents. *J Pediatr Surg* 2013;48:178–83.
286. Andersson S, Lonroth H, Simren M, et al. Gastric electrical stimulation for intractable vomiting in patients with chronic intestinal pseudoobstruction. *Neurogastroenterol Motil* 2006;18:823–30.
287. Minneci PC. Intestinal transplantation: An overview. *Pathophysiology* 2014;21:119–22.
288. Ganousse-Mazeron S, Lacaille F, Colomb-Jung V, et al. Assessment and outcome of children with intestinal failure referred for intestinal transplantation. *Clin Nutr* 2015;34:428–35.
289. Sheth J, Sharif K, Lloyd C, et al. Staged abdominal closure after small bowel or multivisceral transplantation. *Pediatr Transplant* 2012;16:36–40.
290. Goulet O, Lacaille F, Colomb V, et al. Intestinal transplantation in children: Paris experience. *Transplant Proc* 2002;34:1887–8.
291. Loinaz C, Rodriguez MM, Kato T, et al. Intestinal and multivisceral transplantation in children with severe gastrointestinal dysmotility. *J Pediatr Surg* 2005;40:1598–604.
292. Millar AJ, Gupte G, Sharif K. Intestinal transplantation for motility disorders. *Semin Pediatr Surg* 2009;18:258–62.
293. Halter JP, Michael W, Schupbach M, et al. Allogeneic haematopoietic stem cell transplantation for mitochondrial neurogastrointestinal encephalomyopathy. *Brain* 2015;138:2847–58.
294. Abu-Elmagd KM, Kosmach-Park B, Costa G, et al. Long-term survival, nutritional autonomy, and quality of life after intestinal and multivisceral transplantation. *Ann Surg* 2012;256:494–508.
295. Hukkinen M, Merras-Salmio L, Sipponen T, et al. Surgical rehabilitation of short and dysmotile intestine in children and adults. *Scand J Gastroenterol* 2015;50:153–61.
296. Beath S, Pironi L, Gabe S, et al. Collaborative strategies to reduce mortality and morbidity in patients with chronic intestinal failure including those who are referred for small bowel transplantation. *Transplantation* 2008;85:1378–84.
297. Lauro A, De Giorgio R, Pinna AD. Advancement in the clinical management of intestinal pseudo-obstruction. *Expert Rev Gastroenterol Hepatol* 2015;9:197–208.
298. Ueno T, Wada M, Hoshino K, et al. A national survey of patients with intestinal motility disorders who are potential candidates for intestinal transplantation in Japan. *Transplant Proc* 2013;45:2029–31.
299. Smith JM, Skeans MA, Horslen SP, et al. Intestine. *Am J Transplant* 2016;16(Suppl 2):99–114.
300. Smith JM, Skeans MA, Horslen SP, et al. OPTN/SRTR 2013 Annual Data Report: intestine. *Am J Transplant* 2015;15(Suppl 2):1–16.
301. Abu-Elmagd K, Fung J, Bueno J, et al. Logistics and technique for procurement of intestinal, pancreatic, and hepatic grafts from the same donor. *Ann Surg* 2000;232:680–7.
302. Mazariegos GV, Abu-Elmagd K, Jaffe R, et al. Graft versus host disease in intestinal transplantation. *Am J Transplant* 2004;4:1459–65.
303. Plant AS, Venick RS, Farmer DG, et al. Plasmacytoma-like post-transplant lymphoproliferative disorder seen in pediatric combined liver and intestinal transplant recipients. *Pediatr Blood Cancer* 2013;60:E137–9.

304. Ordein JJ, Di Lorenzo C, Flores A, et al. Diversion colitis in children with severe gastrointestinal motility disorders. *Am J Gastroenterol* 1992;87:88–90.
305. Rolston DD, Hunt JB, Fairclough PD, et al. Jejunal water and sodium secretion occurs in chronic idiopathic intestinal pseudo-obstruction. *J Clin Gastroenterol* 1990;12:153–6.
306. Eng C, Clayton D, Schuffenecker I, et al. The relationship between specific RET proto-oncogene mutations and disease phenotype in multiple endocrine neoplasia type 2. International RET mutation consortium analysis. *JAMA* 1996;276:1575–9.
307. Smith VV, Eng C, Milla PJ. Intestinal ganglioneuromatosis and multiple endocrine neoplasia type 2B: implications for treatment. *Gut* 1999;45:143–6.
308. Navarro J, Sonsino E, Boige N, et al. Visceral neuropathies responsible for chronic intestinal pseudo-obstruction syndrome in pediatric practice: analysis of 26 cases. *J Pediatr Gastroenterol Nutr* 1990;11:179–95.
309. Debinski HS, Kamm MA, Talbot IC, et al. DNA viruses in the pathogenesis of sporadic chronic idiopathic intestinal pseudo-obstruction. *Gut* 1997;41:100–6.
310. Nowak TV, Goddard M, Batteiger B, et al. Evolution of acute cytomegalovirus gastritis to chronic gastrointestinal dysmotility in a nonimmunocompromised adult. *Gastroenterology* 1999;116:953–8.
311. Anuras S, Mitros FA, Shirazi SS, et al. Cardiac arrest in two children with nonfamilial chronic intestinal pseudoobstruction on total parenteral nutrition. *J Pediatr Gastroenterol Nutr* 1982;1:137–44.
312. Sood MR, Rudolph CD. Gastrointestinal motility disorders in adolescent patients: transitioning to adult care. *Gastroenterol Clin North Am* 2007;36:749–63xi.
313. Barr JM. Understanding pediatric intestinal pseudo-obstruction: implications for nurses. *Gastroenterol Nurs* 1998;21:11–3.